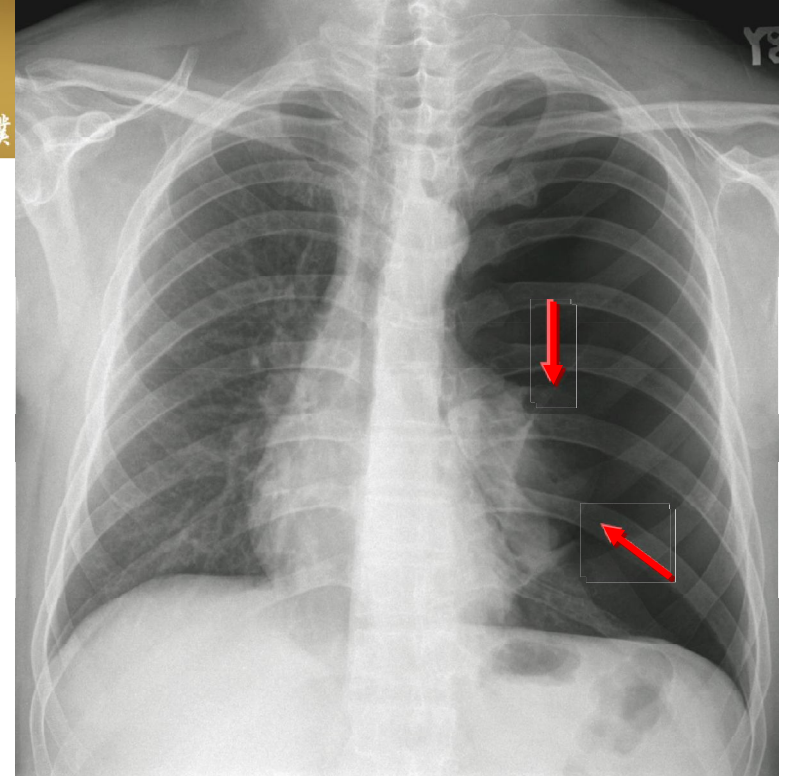


Pneumothorax



Typical signs

- * Visceral pleural line becomes separated from the chest wall
- * Absence of vascular markings beyond visceral pleural margin
- * A small amount of pleural liquid often accompanies a pneumothorax

DDx: The margin of skin folds tends to be much wider than the normal thin visceral pleural line.