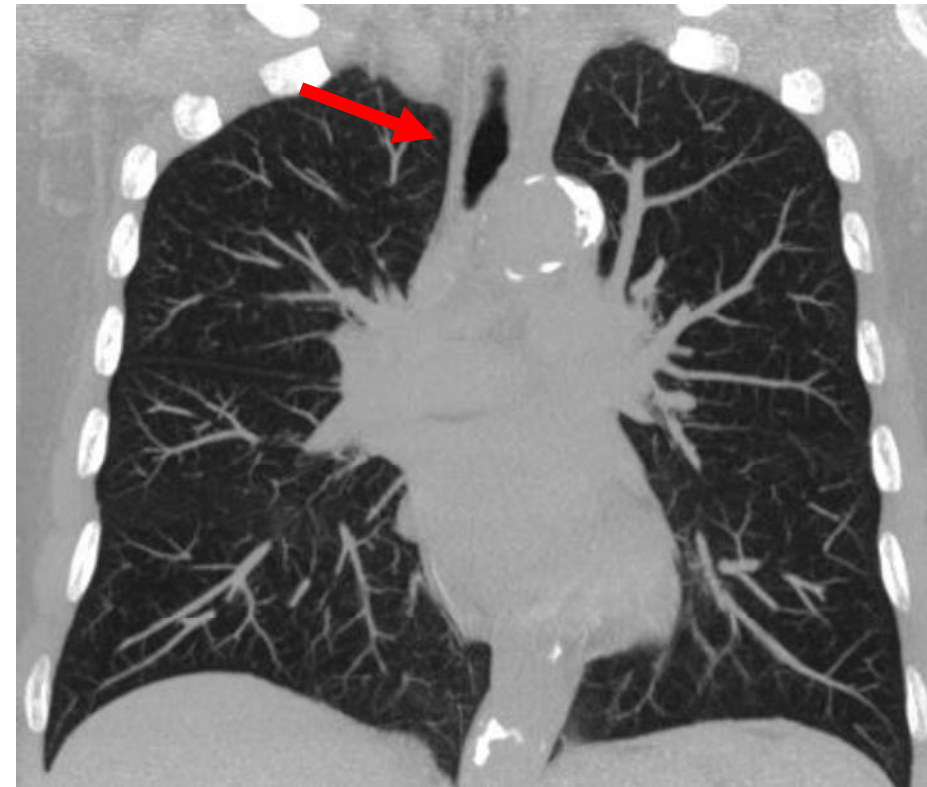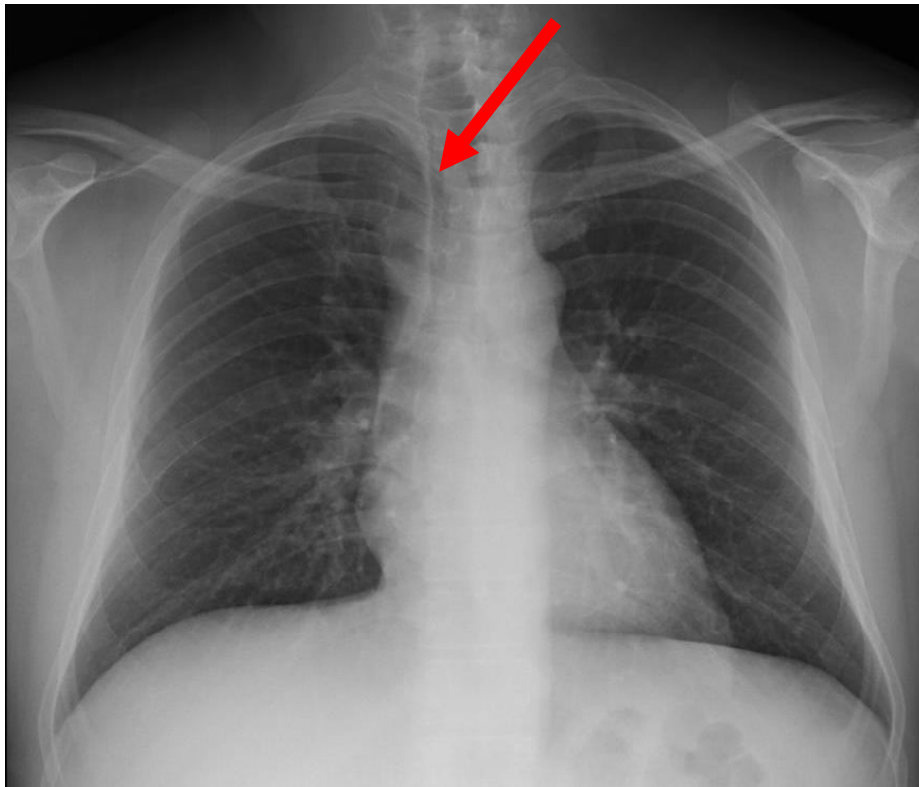


Final diagnosis: Right Para-tracheal Stripe

Key points:

Diagnosis by plain chest finding:  
tracheal wall



Normal right paratracheal stripe (2-3 mm), abnormal soft-tissue density at this area for diagnosis of lymphadenopathy, firstly.