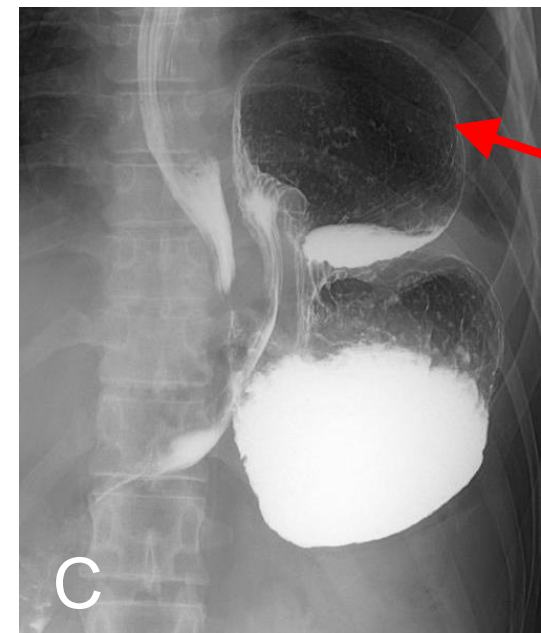
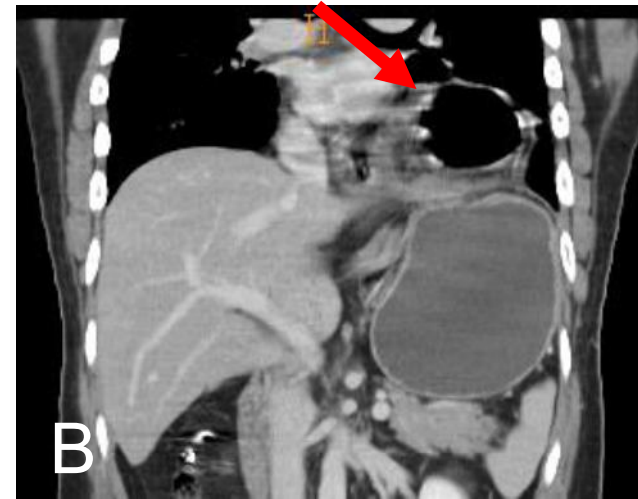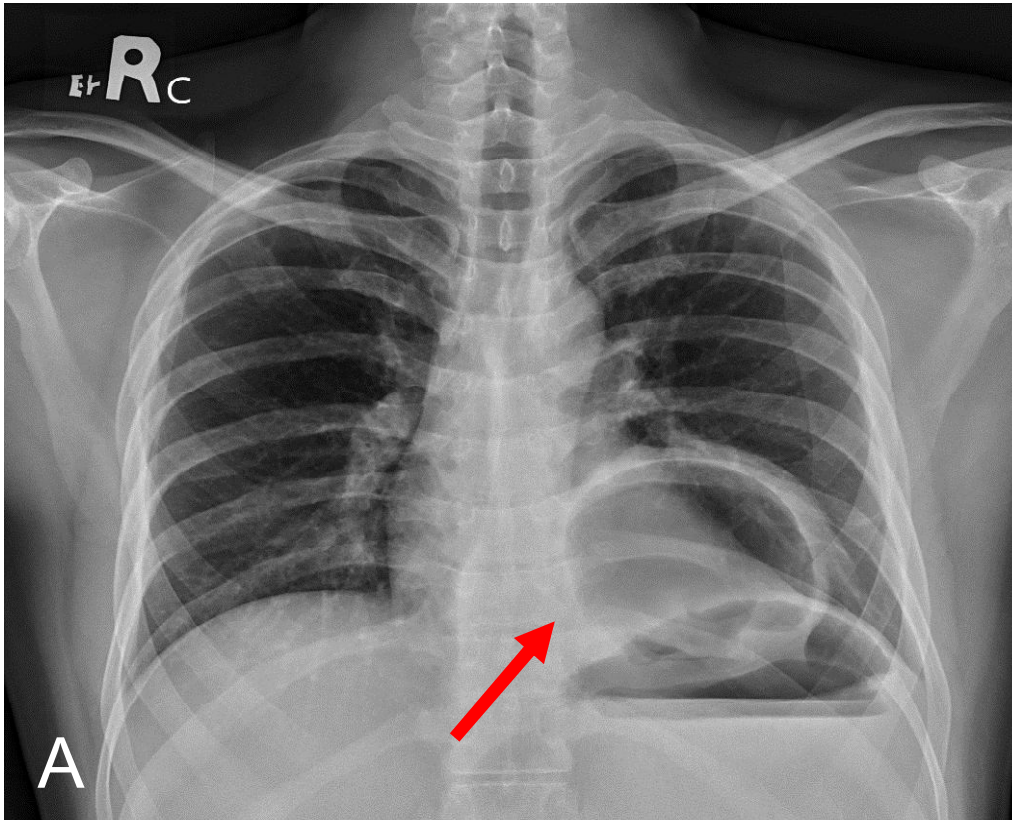


Hiatal hernia, para-esophageal type



Plain chest- abnormal herniated gastric bubble (arrow in A), CT findings, herniated sac (arrow in B), Upper GI series- Hiatal hernia (arrow in C)