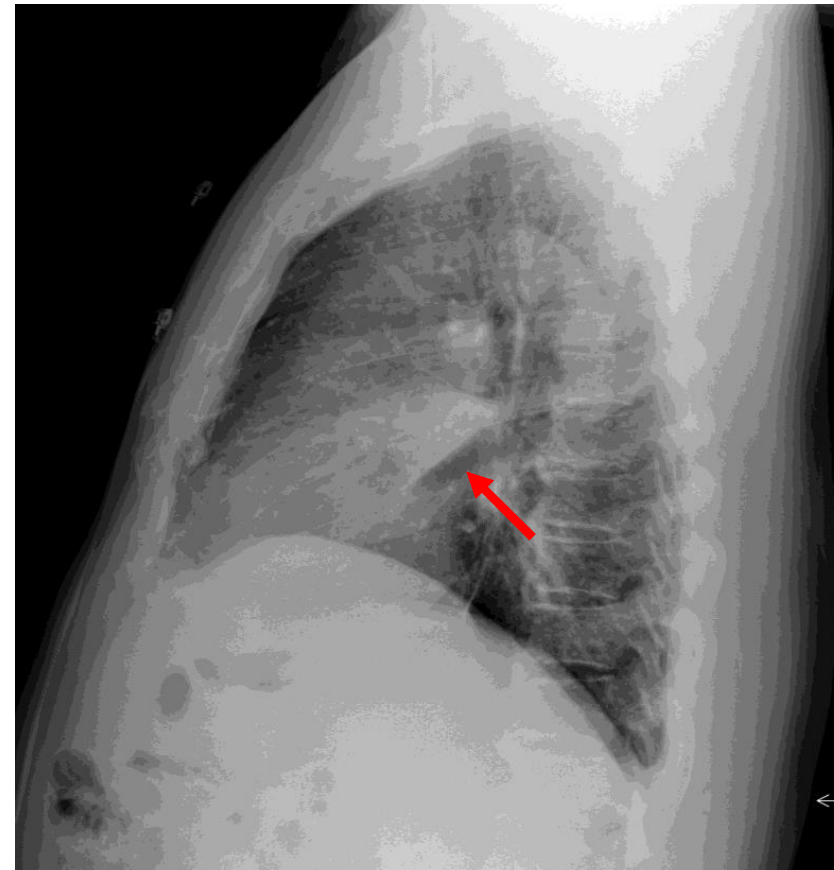
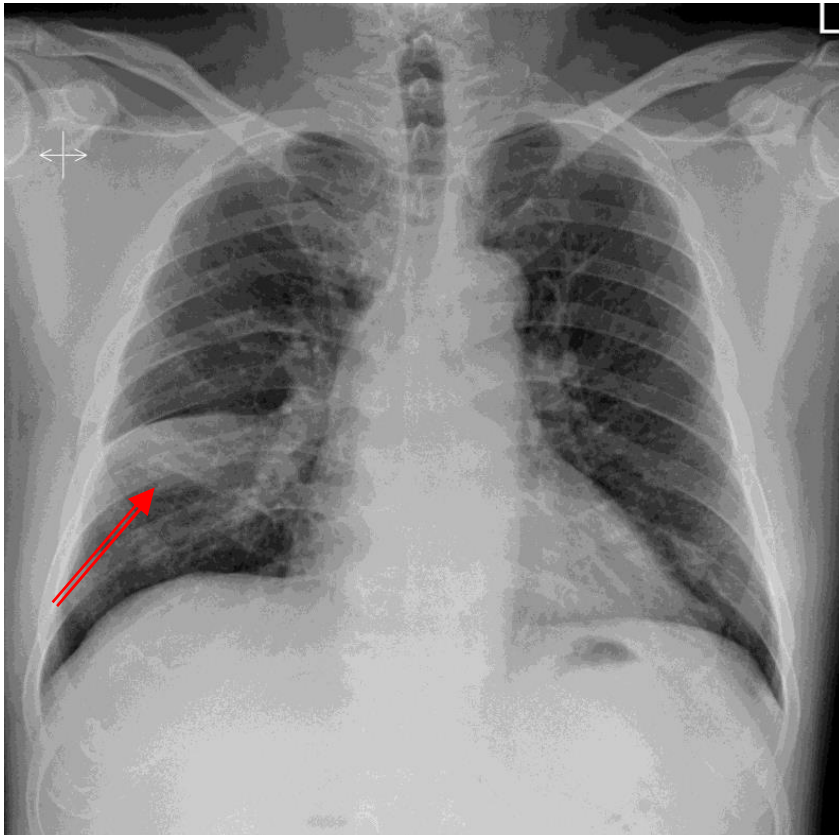


# Final diagnosis: Pneumonia, RML



There is a large patchy consolidative lesion at right middle lung (arrow)