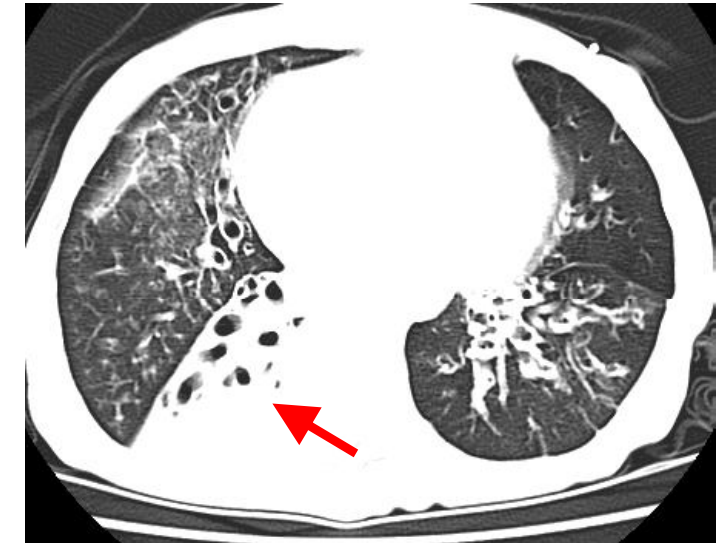
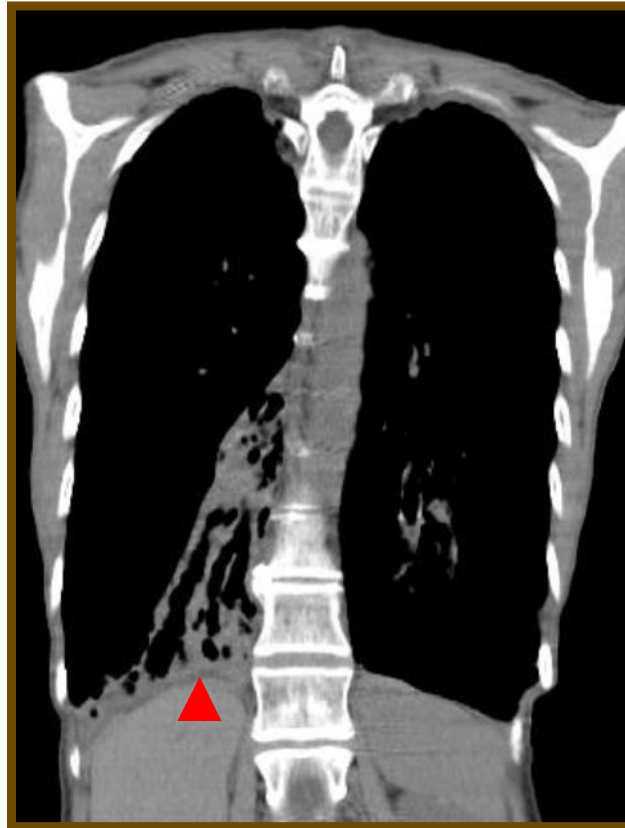
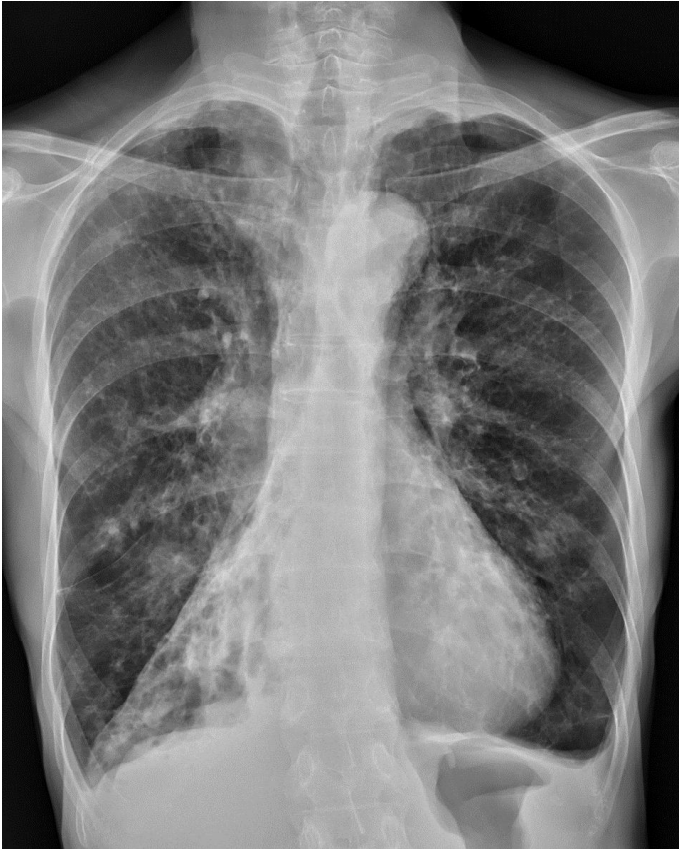
# Final diagnosis: bronchiectasis, RLL



CT images- dilated  
bronchial trees  
(arrow)

Best diagnostic clue: Thickened, cystic bronchi with containing fluid level or tram-tracking appearance (arrow head)