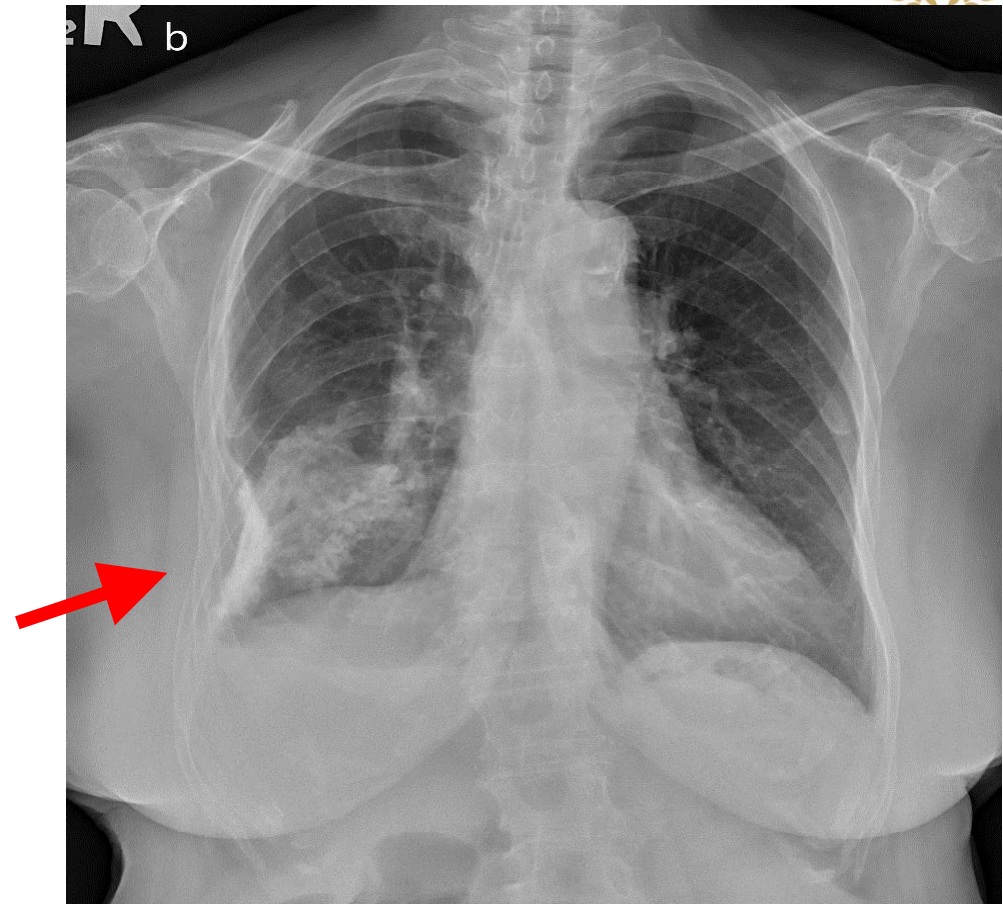


Final diagnosis: Fibrothorax

Heavy pleural calcification
(arrow)



- DDX. Infection such as Tuberculous empyema, Nontuberculous empyema
- DDX. Chest trauma with Hemothorax
- DDX. Mineral inhalation, asbestosis
- Miscellaneous, chronic pancreatitis, chronic hemodialysis, calcified metastasis