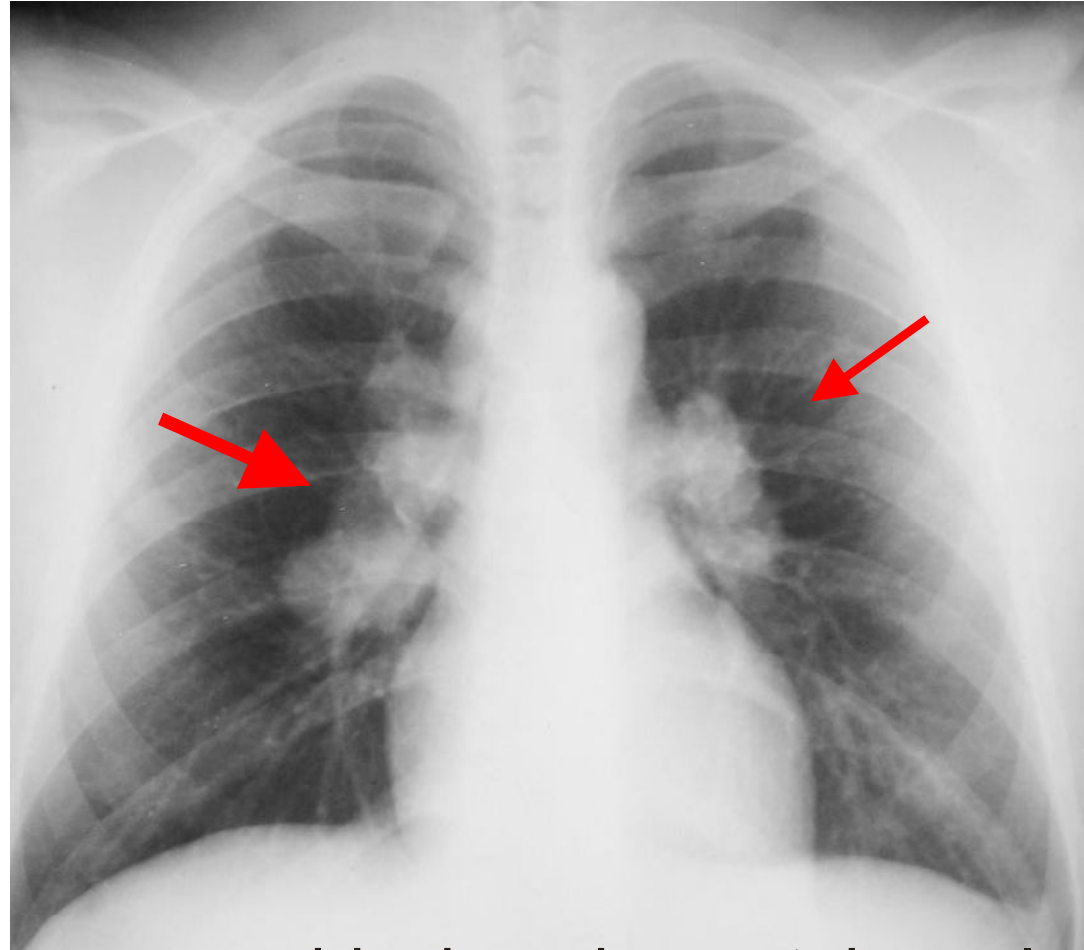


Final diagnosis: sarcoidosis

Bilateral hilar enlarged lymph nodes (arrow)



DDx. hilar adenopathy such as sarcoidosis, primary tuberculosis, malignant lymphoma, Bronchogenic carcinoma (mostly small cell CA type), metastatic lymphadenopathy etc.

DDx. vascular shadow such as primary PAH, COPD etc.