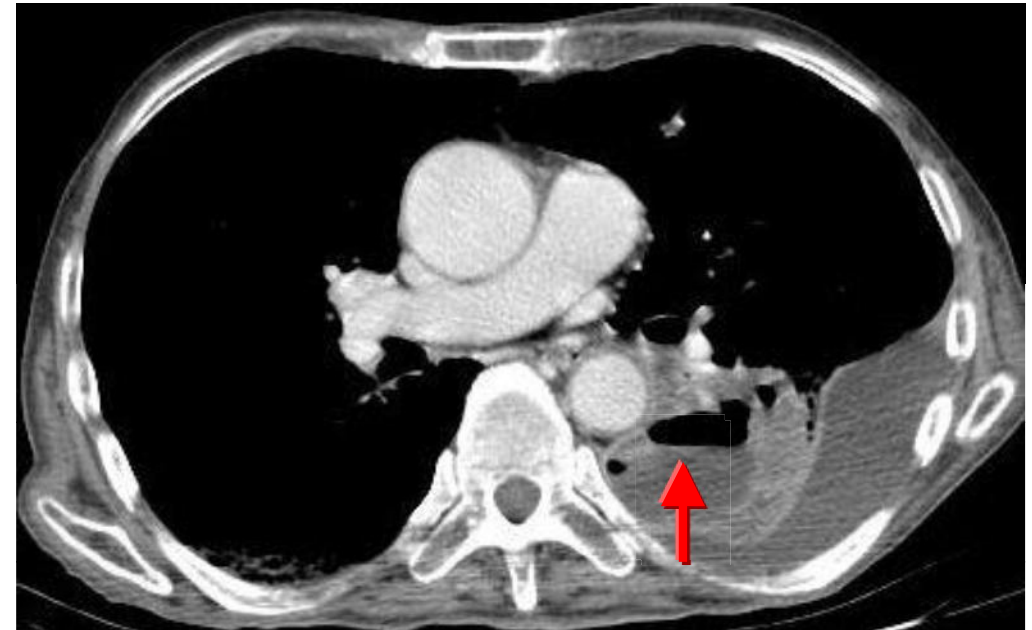
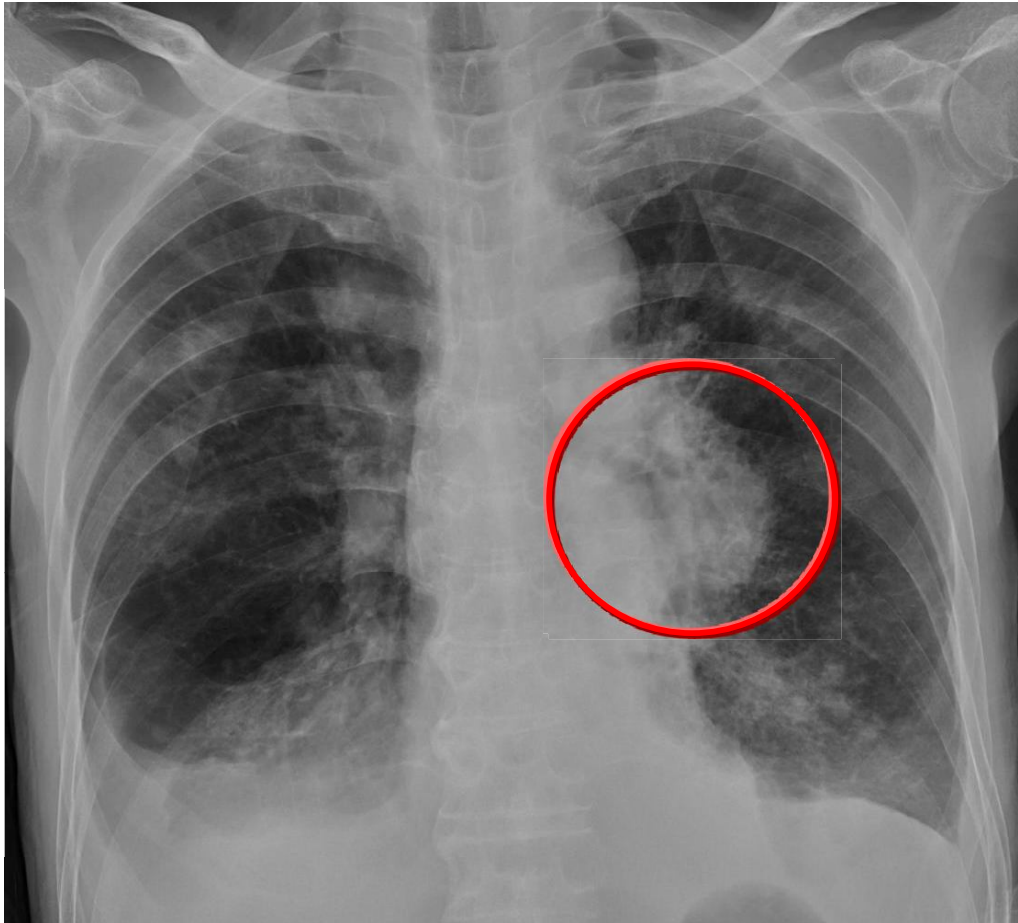


Ans: Lung abscess



Lung abscess is necrosis of the pulmonary tissue and formation of cavities containing necrotic debris or fluid. The causative organisms could be anaerobic bacteria, aerobic bacteria or fungus. Cavitation lesion with internal air-fluid level are seen in CXR (circle in A & CT (arrow).