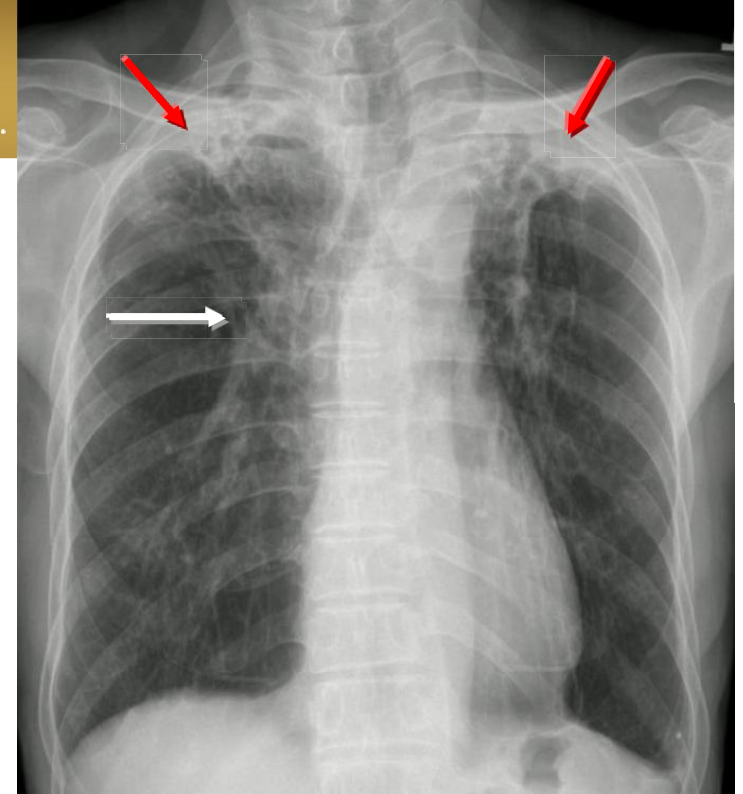


Pulmonary TB



■ 診斷重點:

- Fibrotic change (red arrows) in bilateral apical lungs with elevation of bilateral hila (white arrow)
- In active pulmonary TB, infiltrates or consolidations and/or cavities are often seen in the upper lungs with or without mediastinal or hilar lymphadenopathy.
- Old healed tuberculosis usually presents as pulmonary nodules in the hilar area or upper lobes, with or without fibrotic scars and volume loss.