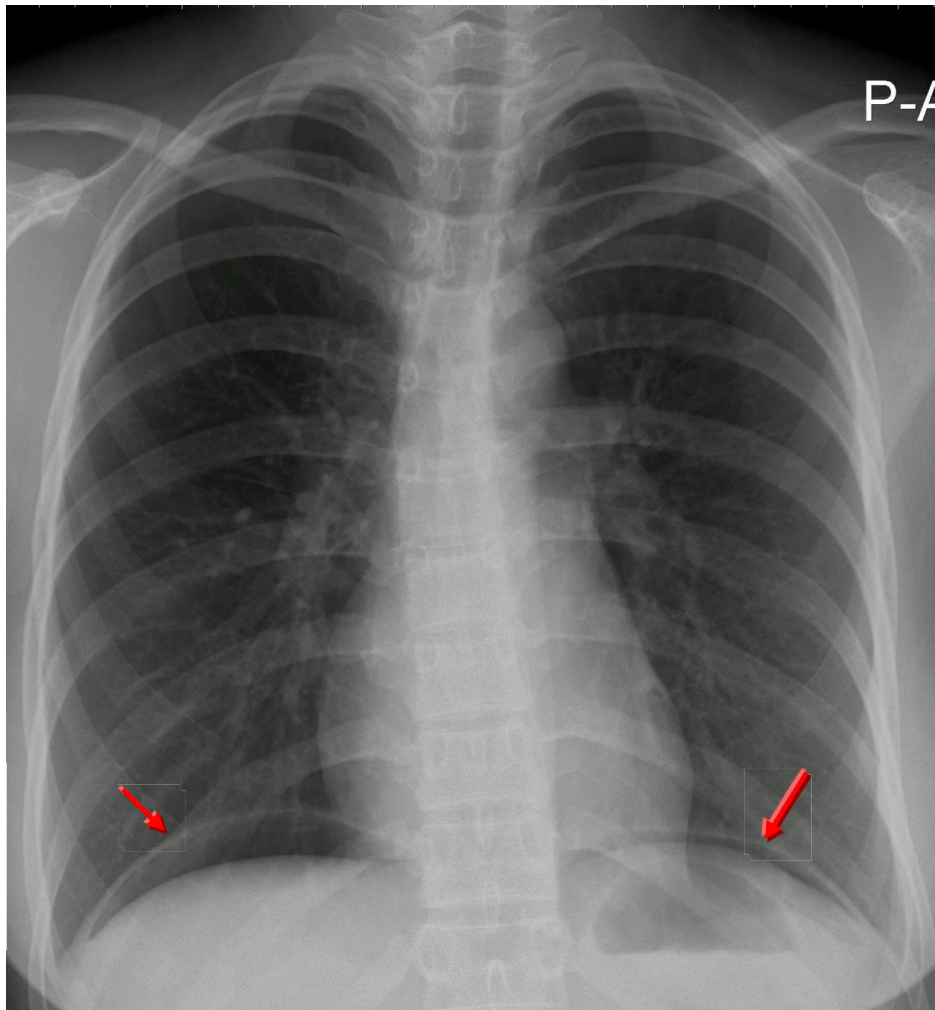


Pneumoperitoneum



- This patient has a large volume of free gas under the diaphragm.
- Dark crescents have formed separating the thin diaphragm from the liver on the right, and bowel on the left.
- This patient had a perforated duodenal ulcer.
- The patient should be positioned sitting upright for 10-20 minutes prior to acquiring the erect chest X-ray image.