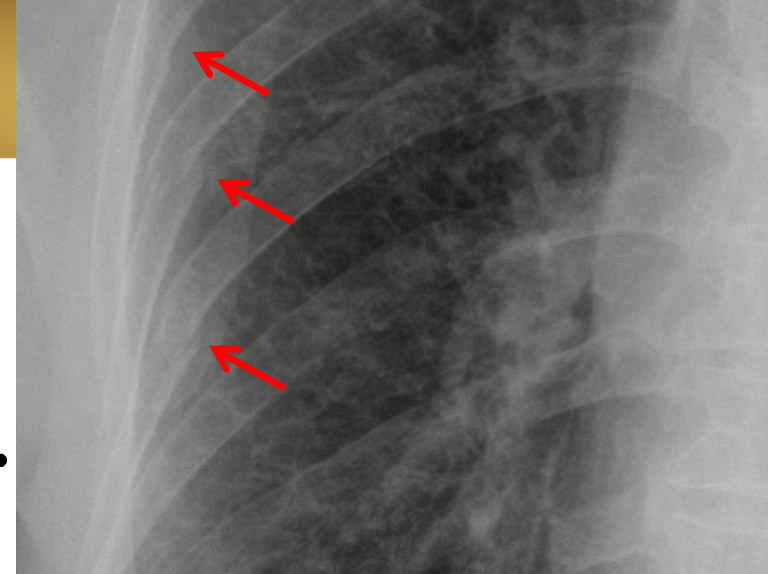


Ribs fracture

- right 5th, 6th, 7th ribs fr.



- Cortical disruption of the bone.
- A chest X-ray should be obtained to exclude pneumothorax or pulmonary contusion.
- DDX: pathological fracture
 - Fractures without significant trauma
 - Combined with osteolytic or osteoblastic bone mass