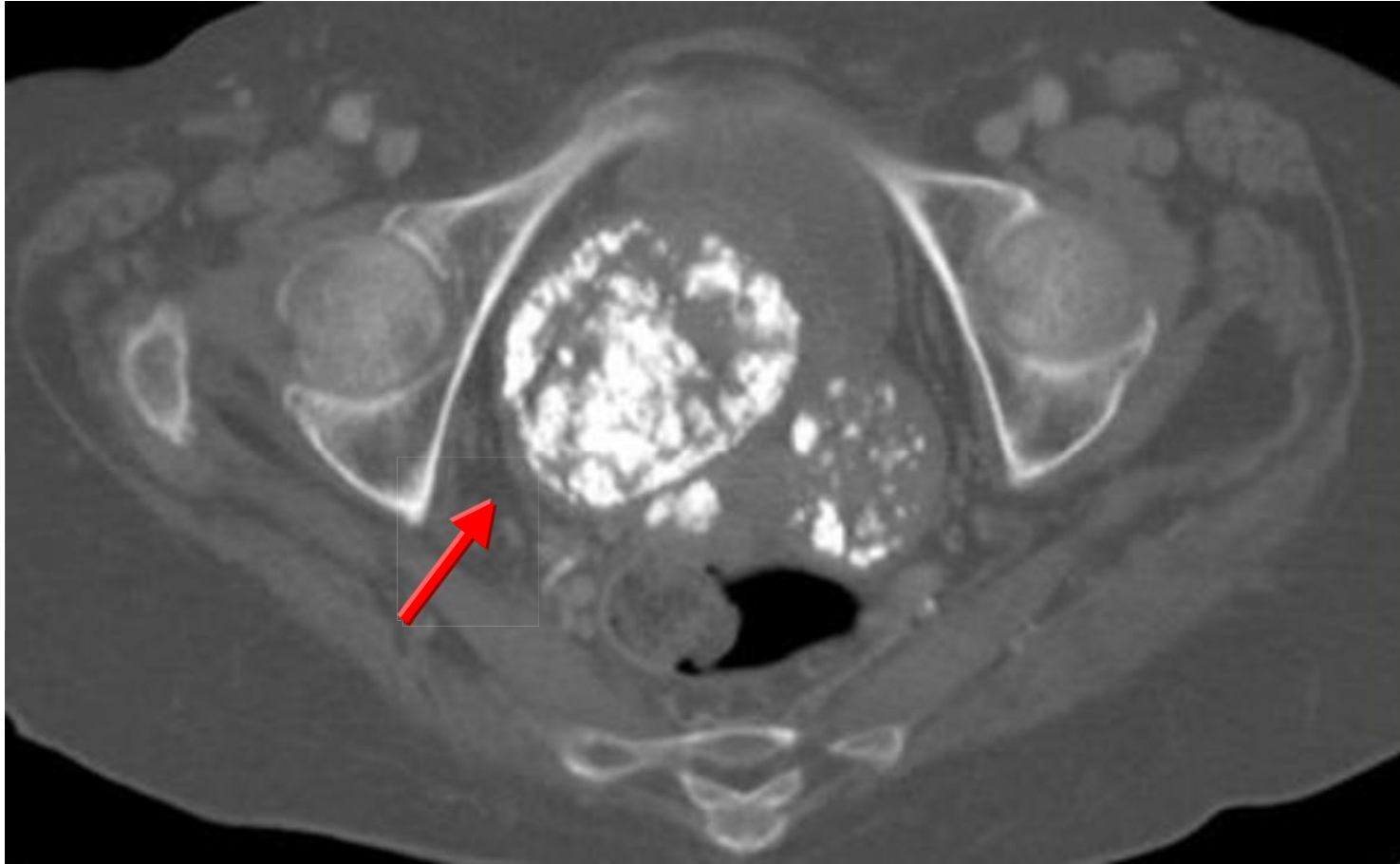


Calcified uterine fibroid



Uterine fibroids (arrow) are the most common benign gynecologic tumors, hyaline degeneration of uterine fibroids lead tumor calcification. During menopause, there is a tendency to increased incidence of fibroid calcification.