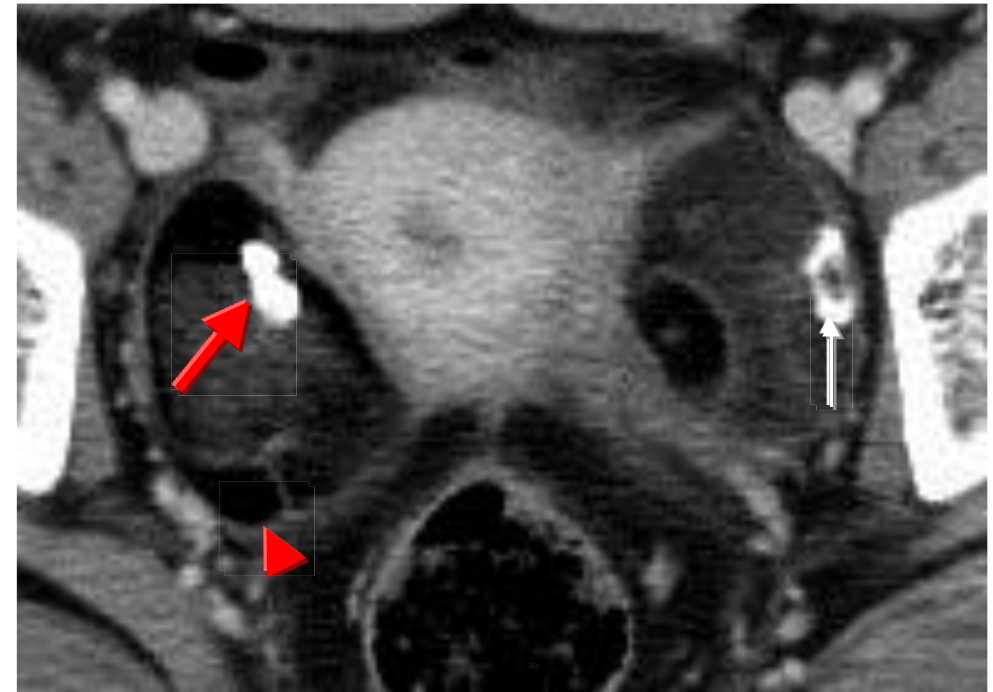
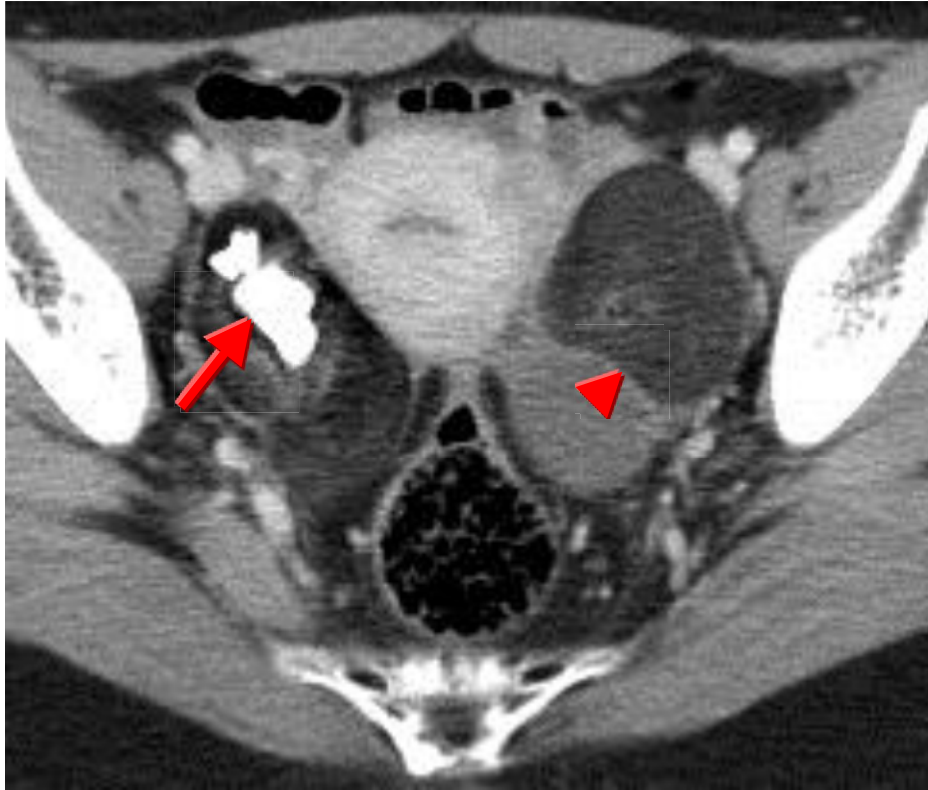


Bil. Dermoid cysts



A benign tumor of ovary origin from ectoderm contains different recognizable tissues including hair, bone and sebaceous (oily) material (arrow head), neural tissue and teeth (arrow). Up to 15% occurs in both ovaries & age of initial detection is in the childbearing years.