

**CASE 3**

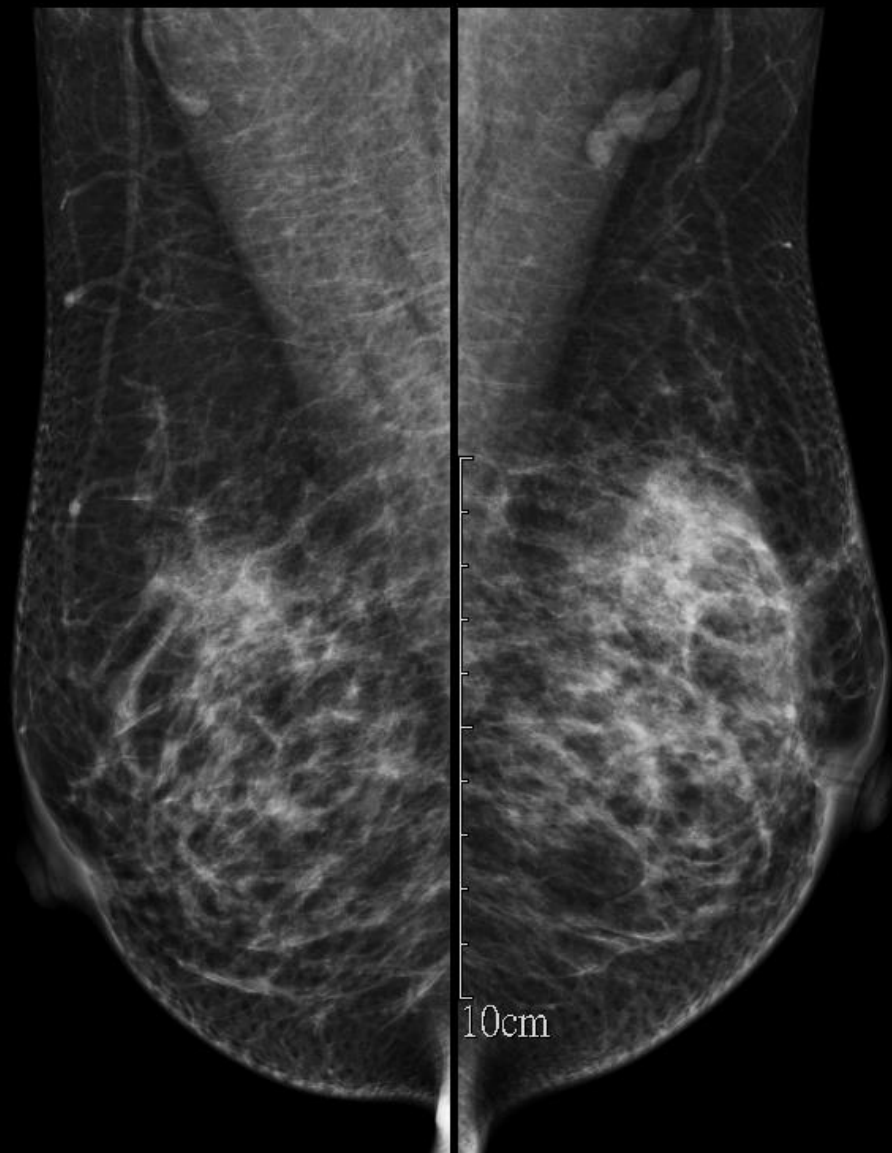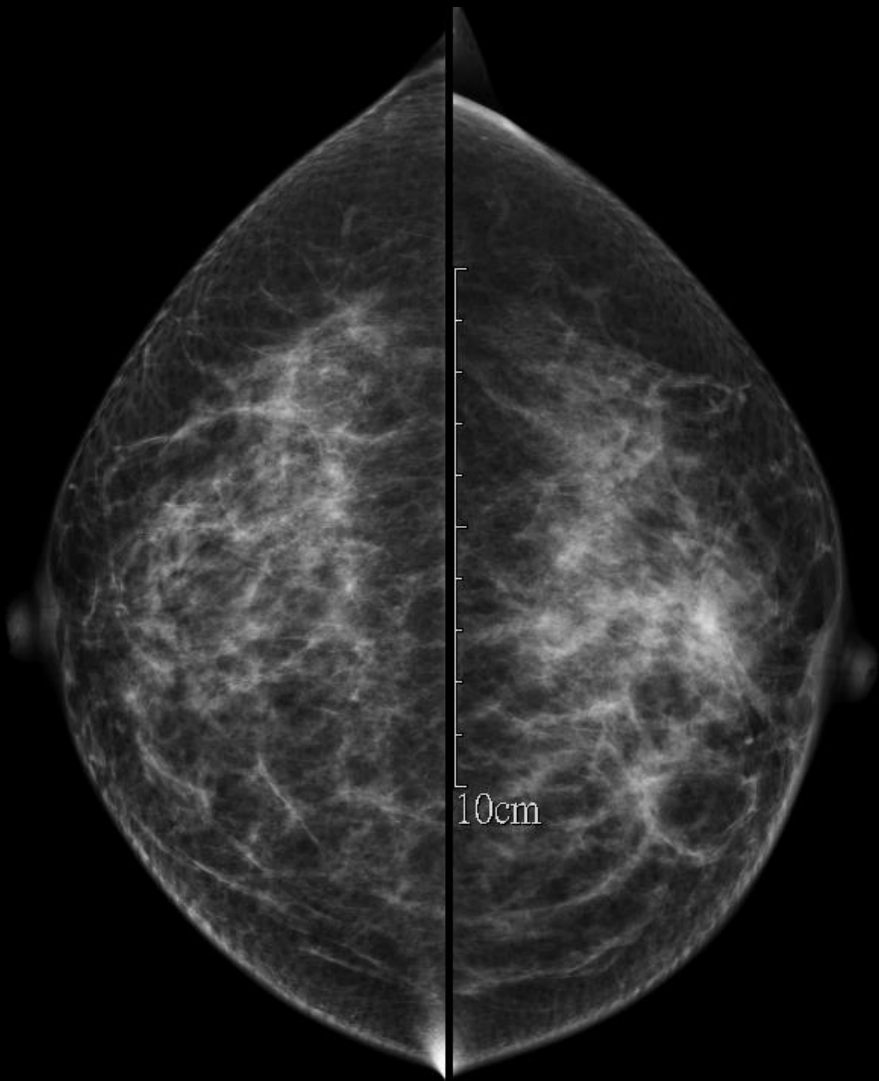
**35 Y/O WOMAN**

# Brief history

- 35 years old woman
- PHx: denied
- Chief complain :
  - Left breast mass

# Imaging study

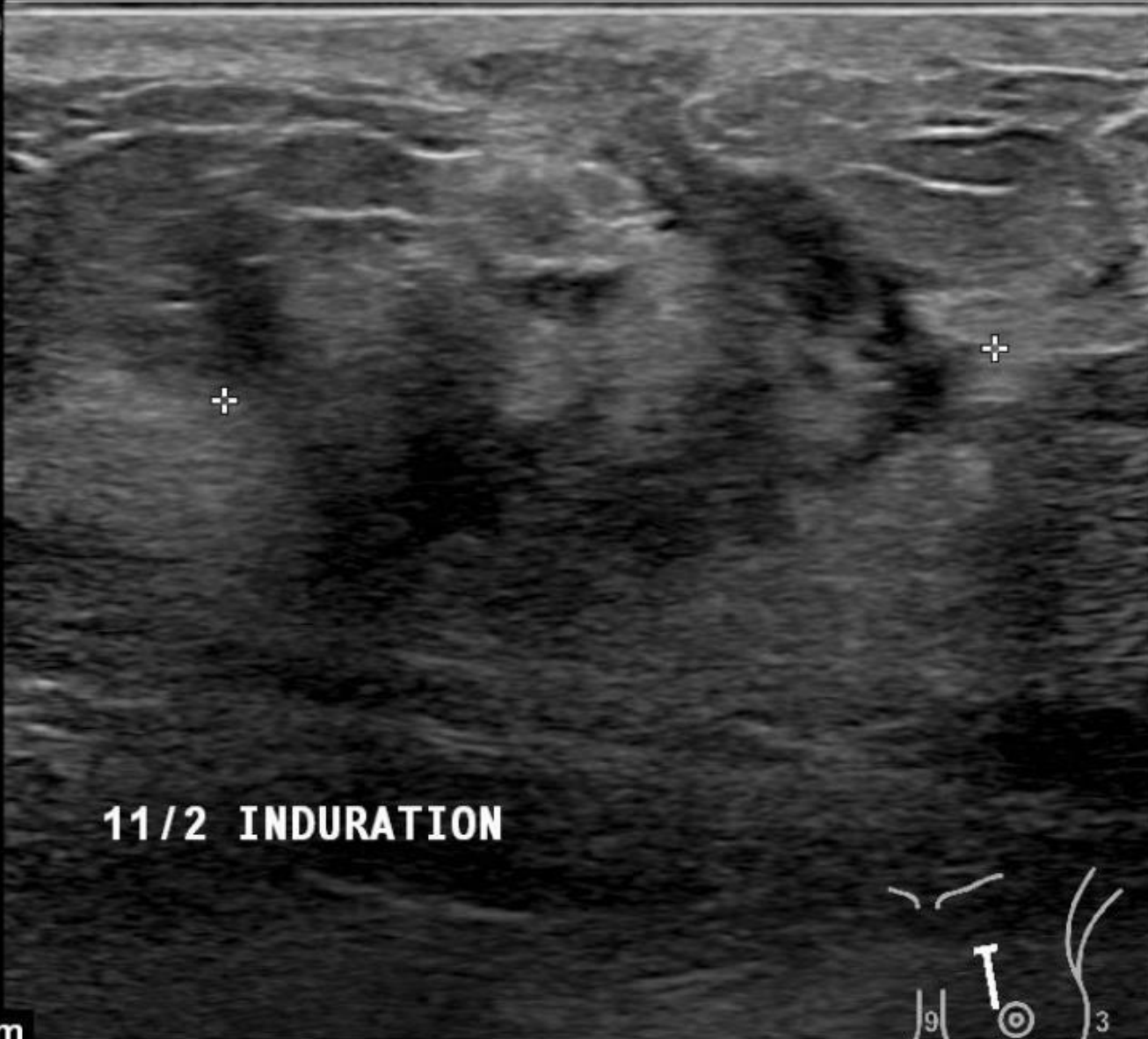- 2020 Mammography
- 2020 sonography



L12-5  
34Hz  
RS

2D  
50%  
Dyn R 61  
P Low  
Res  
TAC1

P



M1

11/2 INDURATION

x2

4.5cm

✦ Dist 33.6 mm

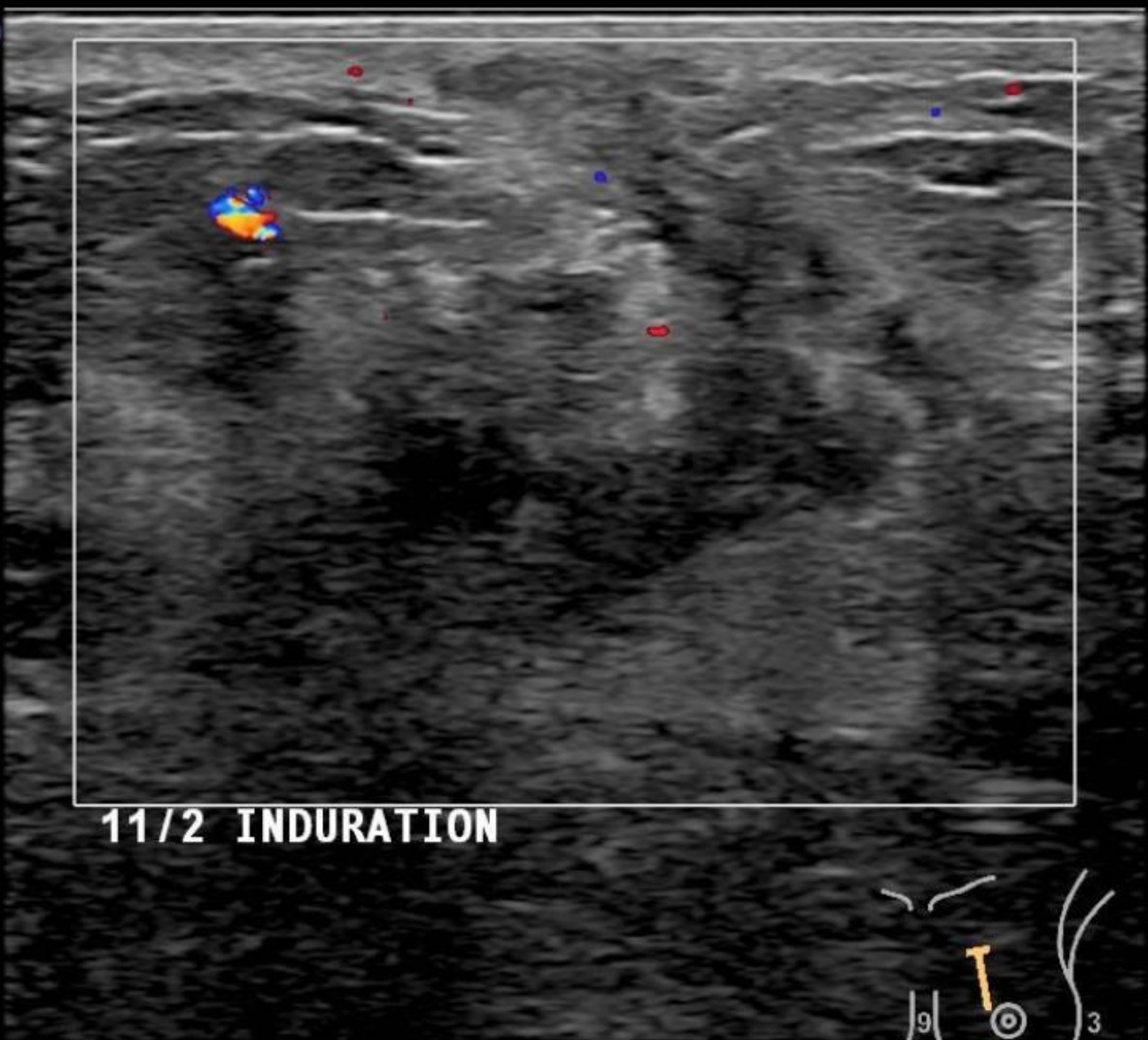

L12-5  
7Hz

P

**2D**  
55%  
Dyn R 60  
P Med  
Res  
TAC1


**CF**  
58%  
406Hz  
WF 22Hz  
6.3MHz



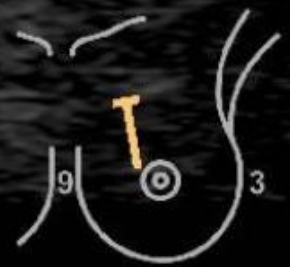11/2 INDURATION

X2

M1 M6  
+2.5



-2.5  
cm/s



4.5cm

# Pathology

- mastitis