

**CASE 5**

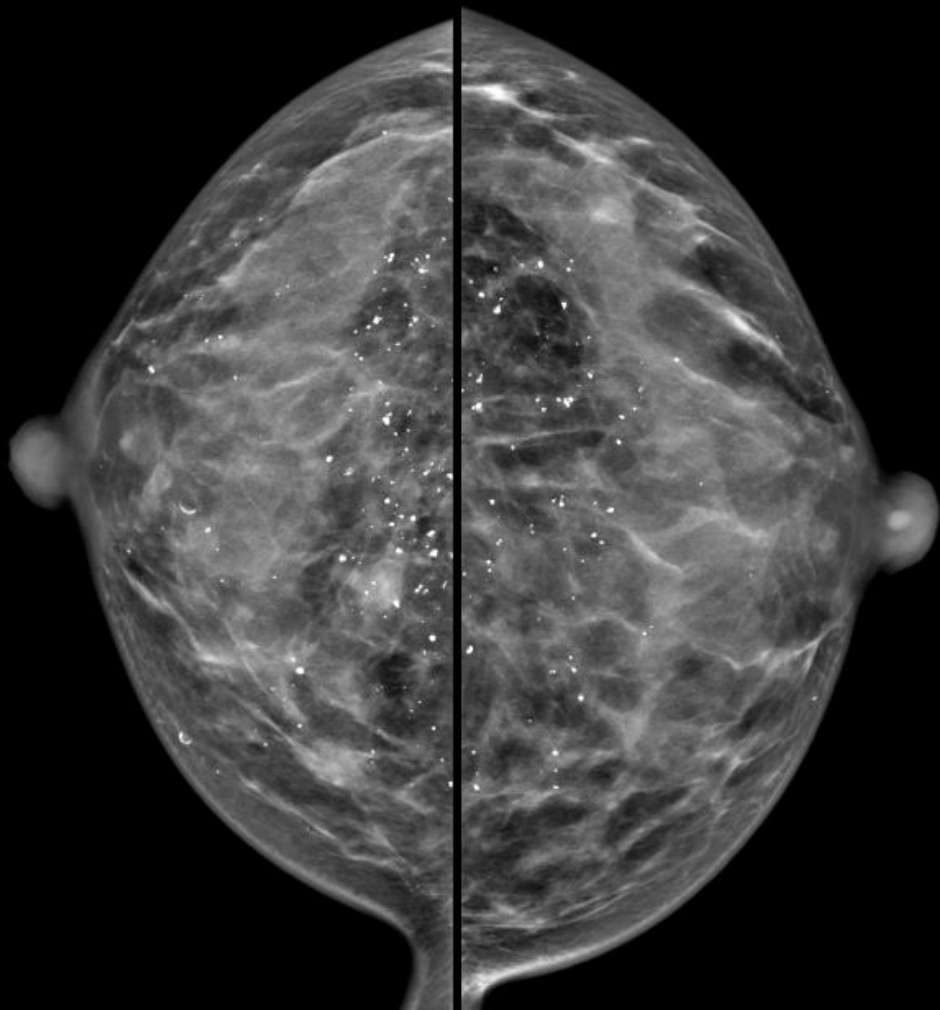
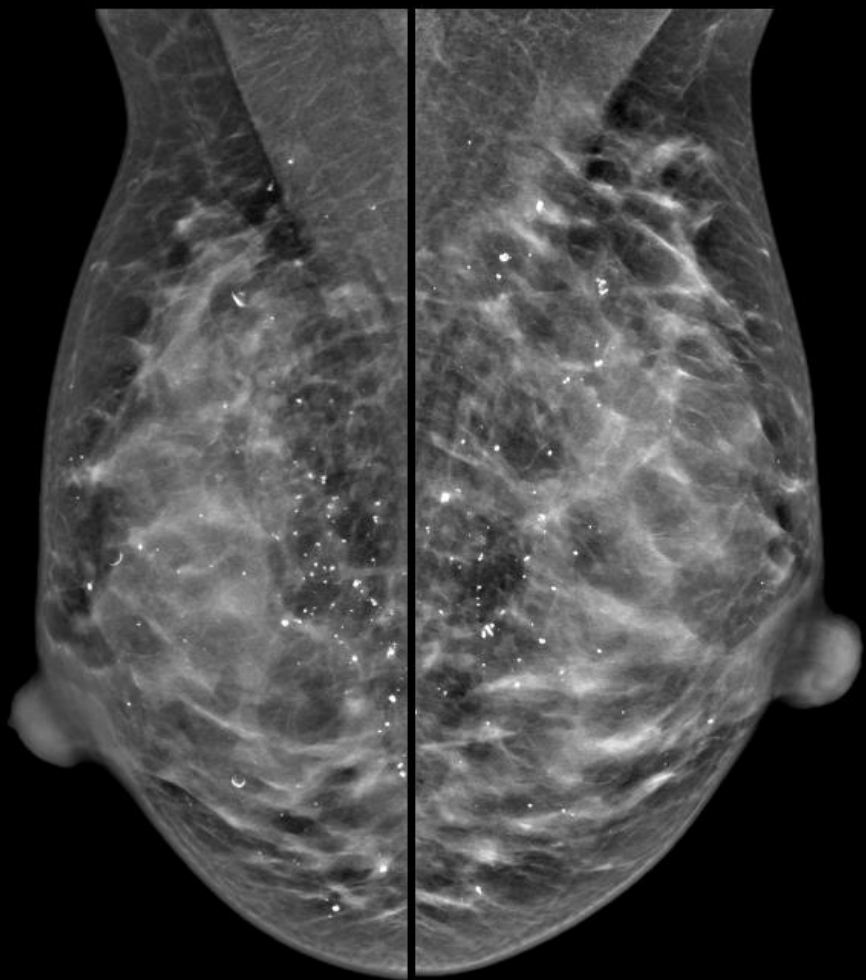
**35 Y/O WOMAN**

# Brief history

- 35 years old woman
- PHx: Denied
- Chief complain:
  - Suspect breast lump

# Imaging study

– 2020 Tomo



# Past history

- autologous fat injection

- END