

CASE 5

83 Y/O M

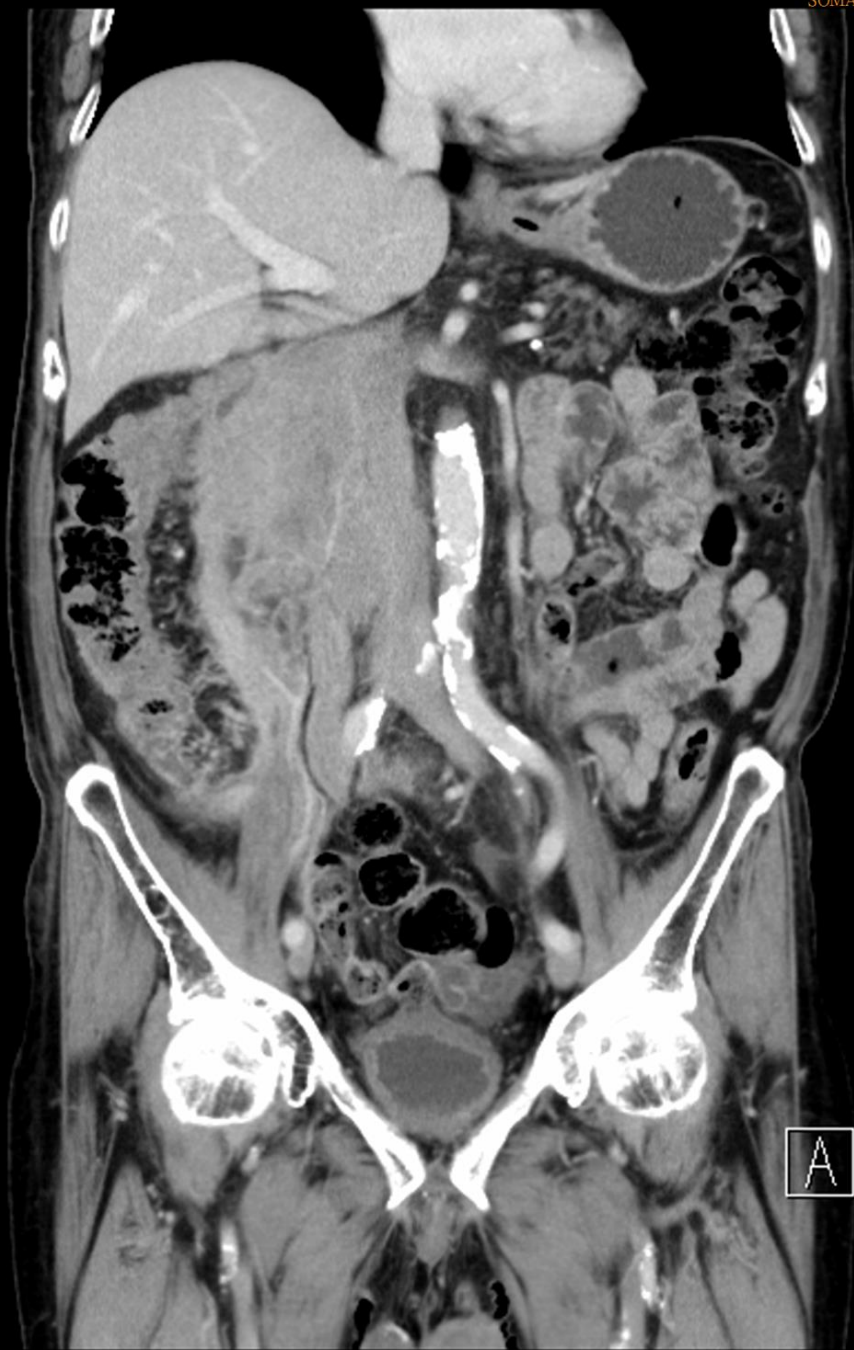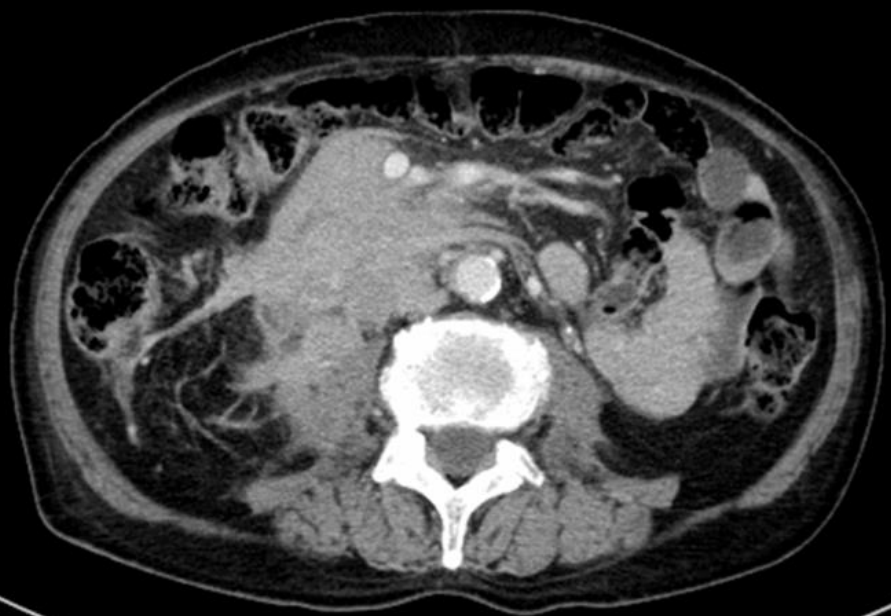
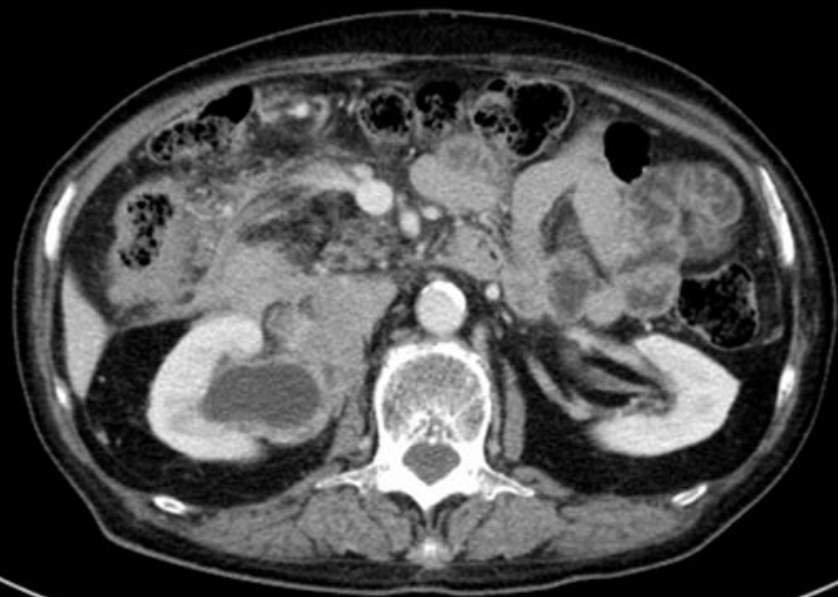Brief history

- **Past history**

Prostate cancer , cT3bN0M0 , s/p robotic assisted radical prostatectomy + Bilateral pelvic lymph node dissection + Chemotherapy

- **Chief complain**

regular f/u CT



Differential diagnosis

- primary neoplasm of urinary system or small intestine
- Lymphoma
- metastasis

病理編號	TH2423334	病歷號碼	16407682	送檢醫師	葉劭德	病床	9B133		
姓名	張添福	科別	泌尿科	出生日期	1941-03-15	年齡	83	性別	男
組織由來	right retroperitoneal tumor				報告日期	2024-09-24 15:29			
臨床診斷	right retroperitoneal tumor								

病理診斷

Soft tissue, retroperitoneum, biopsy, presence of dermal tissue

檢查報告

The specimen submitted consists of five tissue fragments, measuring up to 0.5 x 0.1 x 0.1 cm in size, fixed in formalin.

Grossly, they are gray and soft.

All for section.

Microscopically, it shows fragments of unremarkable dermal tissue with adnexa and subcutaneous fat. Re-biopsy is recommended.