

CASE 8

72 Y/O F

Brief history

- **Past history**

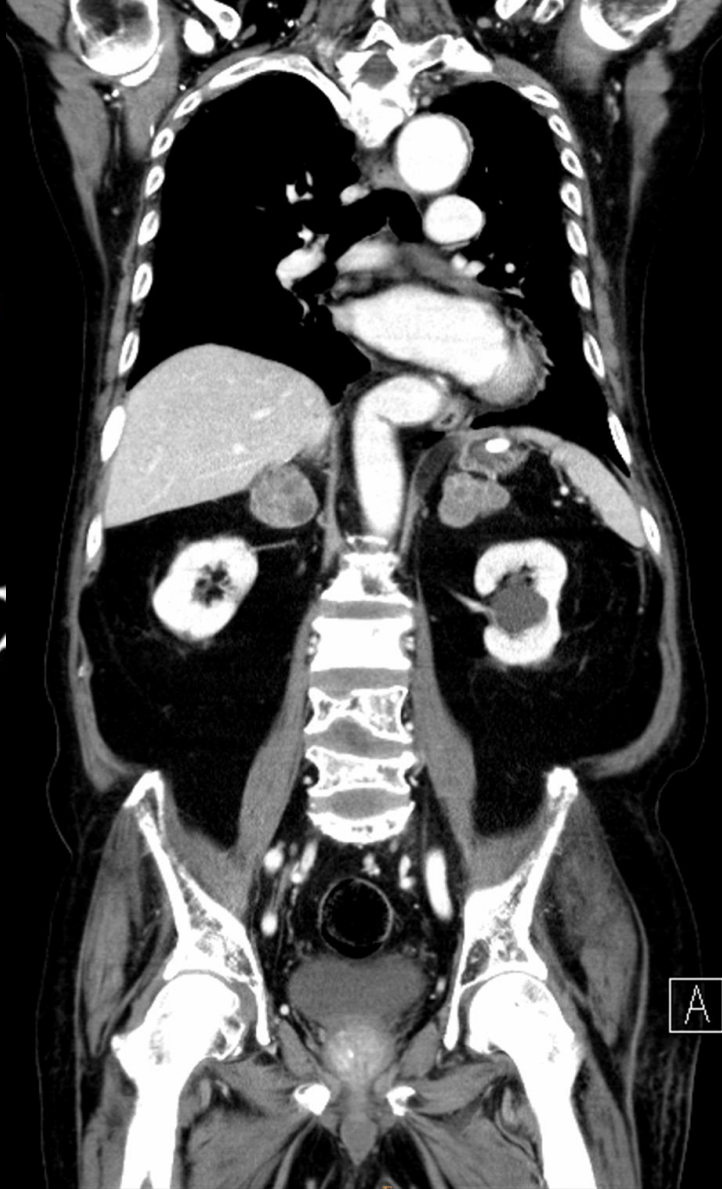
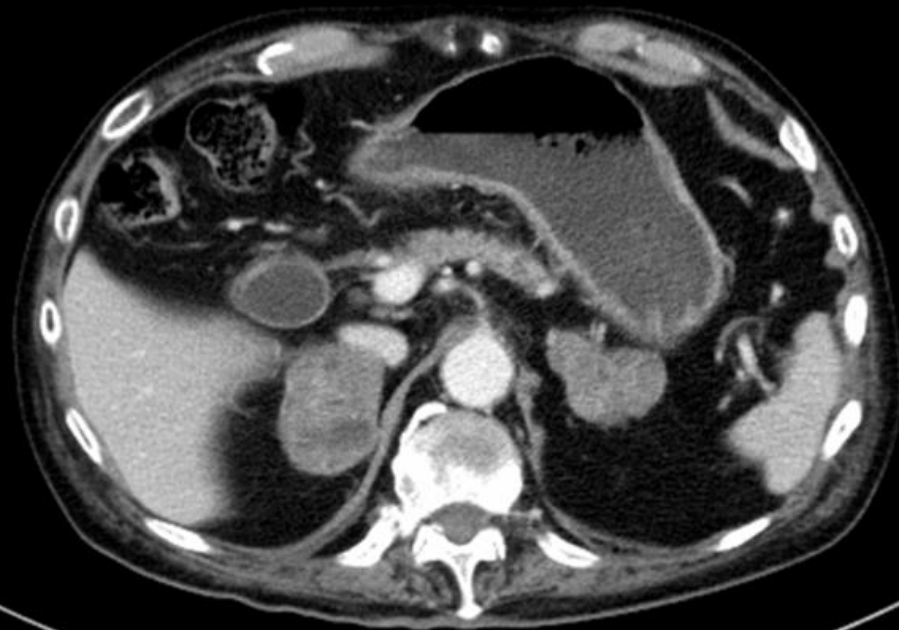Prostate adenocarcinoma, Gleason score 4 + 5 (Grade Group 5) with multiple bone metastasis, cT3aN0M1B, stage IVB

- **Chief complain**

regular F/u

Imaging studies

- 20240415 Chest + Pelvic CT



A

(2024/05/13) Adrenal gland, right, CT-guided biopsy, carcinoma, metastatic

The specimen submitted consists of three tissue fragments, measuring up to 0.2 x 0.1 x 0.1 cm in size, fixed in formalin. Grossly, they are gray and soft. All for section. Microscopically, it shows atypical cells with pleomorphic nuclei, increased N/C ratio and hyperchromasia. Immunohistochemically, NKX3.1 and AMACR are positive. It is compatible with metastatic carcinoma of prostate origin.

報告登打：李宛庭醫師 (病解專醫字第000681號) 2024/05/17 00:00，覆閱：林永和醫師 (員編 861084)

病理號碼 TH2411364 報告日期 2024-05-17

Diagnosis of Prostate cancer

- PIRADS4
 - 20167602
 - 20235776
 - 05631027
 - 11808839
 - 19722706
- 02718693 T2a → clinical T3a
- 02441551 only bone post biopsy image
- 16116612 T2c → patho T3a