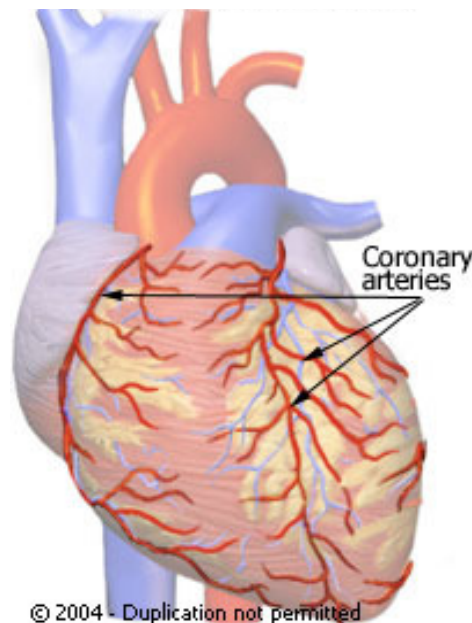


Coronary Anomalies

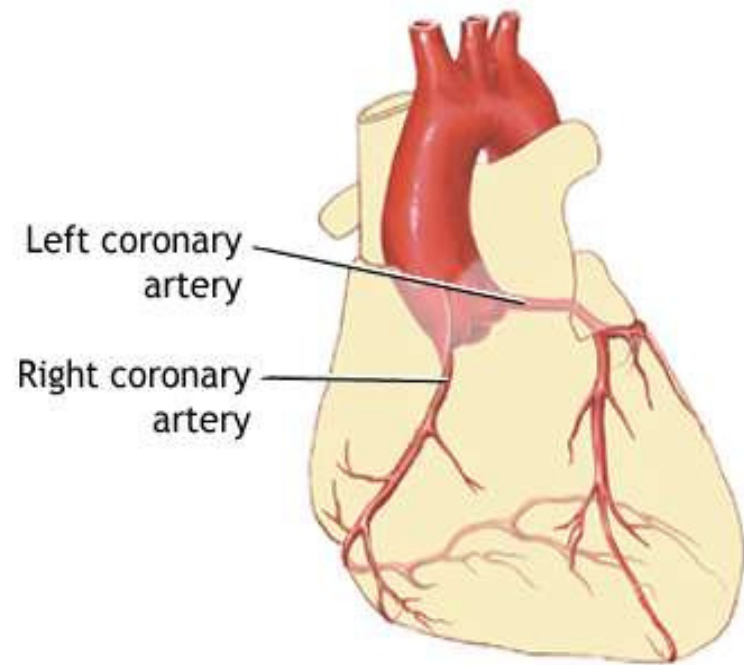
Intern 許書菁

Normal coronary arteries

- The name and nature of a coronary artery or branch is defined by that vessel's distal vascularization territory, not by its origin.



- LAD: anterior wall and superior 2/3 of the septum
- CX: lateral and posterior wall
- RCA: inferior wall and inferior 1/3 of the septum



adam.com

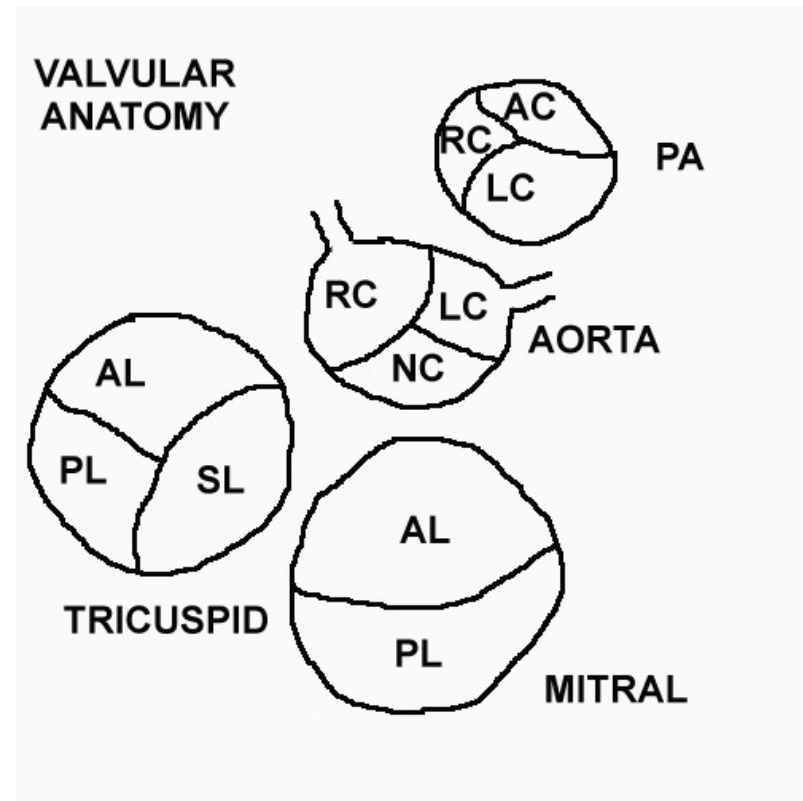
Normal VS Anomaly

- *Normal*
any morphological feature observed in $>1\%$ of an unselected population
- *normal variant*
an alternative, relatively unusual, morphological feature seen in $>1\%$ of the same population
- *Anomaly*
a morphological feature seen in $<1\%$ of that population

Normal

- Normally, coronary arteries have two or three coronary ostia.
- Two ostia (the right and left) are typically present.
- The third coronary artery , or conal or infundibular branch is present in 23-51% of normal hearts

- AC = anterior cusp,
- RC = right cusp,
- LC = left cusp,
- NC = non coronary cusp,
- PL = posterior leaflet,
- AL = anterior leaflet,
- SL = septal leaflet



Anomaly

- Branches of the coronary arteries may vary in origin, distribution, number, and size
- The left coronary artery is more variable than the right.
- In the case of an anomalous right coronary trunk, there are usually no dire consequences. In the case of an anomalous left coronary trunk, the patients usually die of myocardial ischemia at 13 months or longer

Anomalous coronary arteries

- **Anomalous origin**
- **Anomalous origin and course**
- **Anomalous course**
- **Anomalous termination**
- **Abnormal coronary structure**

Anomalous origin

- the left coronary artery (LCA) from the pulmonary artery
- 1/300,000 births
- The ectopic LCA has a variable number of intercoronary collaterals which connect to the otherwise normal RCA.
- There may be segmental left ventricular dysfunction and papillary muscle dysfunction with associated mitral regurgitation.

- the condition is fatal in infancy if it involves the left coronary artery, but is not fatal if it involves the right ventricle
- usually associated with myocardial ischemia, with patients dying at 13 months or younger
- When both coronary arteries arise from the pulmonary trunk, death occurs shortly after birth.

Anomalous origin and course

- Single coronary artery
- Origin from opposite coronary sinus

- the anomalous artery takes 1 of 4 aberrant pathways to reach its proper vascular territory. These pathways are
- type A (anterior to the right ventricular outflow tract)
- type B (between the aorta and pulmonary trunk)
- type C (through the crista supraventricularis portion of the septum)
- type D (dorsal to the aorta).

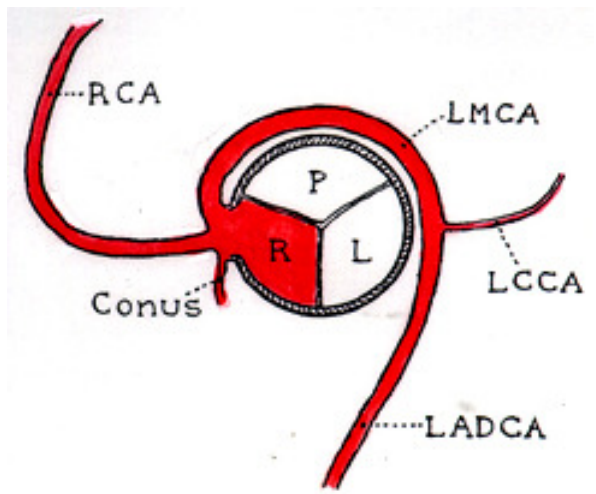
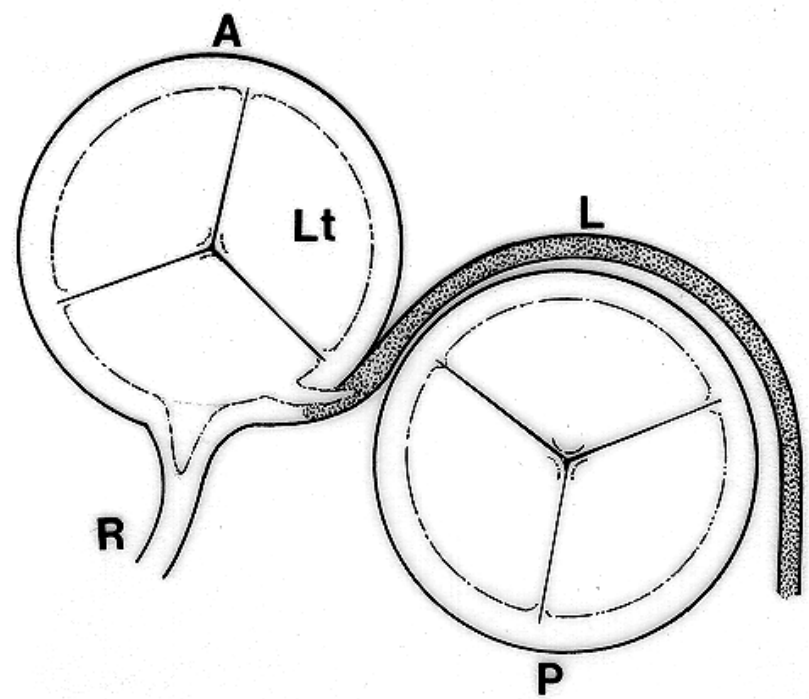


Fig. 1. Diagram showing anomalous origin of left main coronary artery from right aortic sinus with retroaortic coursing of anomalistically arising artery.



Anomalous course

- Otherwise normal coronary arteries may have an intramyocardial course (ie, myocardial bridge). This particular abnormality involves a variable length of the vessel and is observed most commonly in the proximal portion of the LAD coronary artery.

Anomalous termination

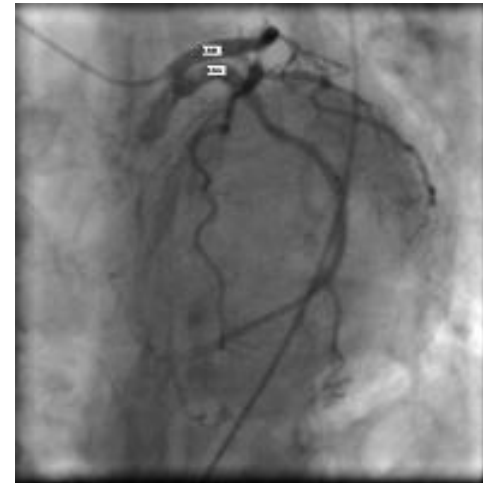- Major epicardial coronary arteries may terminate abnormally into one of the cardiac chambers, the coronary sinus, or the pulmonary trunk and, thus, produce fistulas.
- These fistulas can originate from the left coronary artery system (50-60%), right coronary artery system (30-40%), or both (2-5%). Most fistulas (90%) drain into the right heart.

Abnormal coronary structure

- Coronary artery atresia is characterized by the presence of an ostial dimple in the left or right aortic sinus that terminates in a cordlike fibrotic structure without a patent lumen. Atresia may also involve individual major epicardial coronary arteries. Hypoplastic coronary arteries have small luminal diameter (usually <1 mm) and reduced length. The latter is often associated with the absence of the posterior descending coronary artery.

BENIGN CORONARY ANOMALIES

- Incidence...1.07%, Of all anomalies...80.6%.
- a) Separate origin of left anterior descending artery and left circumflex from the left sinus Valsalva (0.41% incidence, 30.4% of all anomalies).



- b) Absent left circumflex (with maximally dominant right coronary artery) (0.003% incidence, 0.24% of all anomalies).
- c) Origin of left circumflex from right coronary or right sinus of Valsalva (0.37% incidence, 27.7% of all anomalies).

- d) Ectopic origin of right coronary artery or left main trunk from posterior sinus of Valsalva (Left main trunk; 0.0008% incidence, 0.95% of all anomalies. Right coronary; 0.003%, 0.24% of all anomalies).
- e) Ectopic coronary origin from the ascending aorta (Left main trunk; 16 cases, 0.013% incidence, 0.95% of all anomalies. Right coronary; 188 cases, 0.15% incidence, 11.2% of all anomalies).

- f) Intercoronary communication (0.002% incidence, 0.18% of all anomalies).
- g) Small coronary artery fistulae (0.12% incidence, 9.7% of all anomalies).

POTENTIALLY MORE SERIOUS ANOMALIES

- a) Ectopic coronary origin from the pulmonary artery (Bland-White-Garland syndrome) (Left main trunk from pulmonary; 0.008 % incidence, 0.59% of all anomalies). Left anterior descending; 0.0008% incidence, 0.06% of all anomalies.
- Right coronary artery from pulmonary artery; 0.002% incidence, 0.12% of all anomalies).

- b) Ectopic origin of the left coronary artery from the right sinus of Valsalva Left main trunk from right sinus of Valsalva; 0.017 % incidence, 1.3% of all anomalies.
- Left anterior descending from right sinus of Valsalva; 0.03% incidence, 2.3% of all anomalies.
- Right coronary artery from left sinus of Valsalva; 0.107% incidence, 8.1% of all anomalies.

Frequency

- Coronary artery anomalies are observed in 0.3-1.3% of patients undergoing diagnostic coronary angiography, in approximately 1% of routine autopsy examinations, and in 4-15% of young people who experience sudden death.

- In the general population, the incidence of a single coronary artery is approximately 0.024%, while coronary artery fistulas are found in 0.2% of patients undergoing coronary angiography. Coronary artery fistulas are present in 0.002% of all patients with congenital heart disease.

Mortality/Morbidity

- Most coronary artery anomalies are clinically silent and do not affect the quality of life or lifespan of the affected individuals. Specific forms of anomaly, such as the origin of the left main coronary artery from the pulmonary trunk, the aberrant course of the arteries between the great vessels in association with anomalous and slitlike ostium, and large coronary artery fistulas, may be associated with sudden death, myocardial ischemia, or congestive heart failure. The exact incidence of these associated clinical events is not known.

Sex

- No differences have been reported in incidence of specific coronary artery anomalies among male and female subjects.

Age

- Origin of left main coronary artery from the pulmonary trunk manifests during early infancy.
- Other significant coronary anomalies usually result in symptoms during young adult life.
- The remaining anomalies generally are clinically silent and may be discovered incidentally during noninvasive or invasive diagnostic testing for unrelated symptoms.

Clinical Presentation

- Most patients with coronary artery anomaly remain asymptomatic
- In infants, myocardial ischemia may manifest as episodic crying, tachypnea, or wheezing. The infant may refuse to eat, presumably in order to avoid anginal pain.

- In older individuals, symptoms are reported in less than 30% of patients before a diagnosis of coronary anomaly is made.
- These generally include palpitation, exertional dyspnea, angina or syncope, fatigue, or fever. These symptoms rarely raise clinical suspicion for diagnosis of coronary artery anomalies
- sudden death, myocardial ischemia, congestive heart failure

Sudden death

- the origin of the left main or right coronary arteries from the opposite sinus of Valsalva and the type B (ie, between the aorta and pulmonary trunk) course of the anomalous vessel. This particular anomaly often is associated with a slitlike ostium and an obtuse takeoff of the proximal portion of the vessel. This combination may result in ischemia during exertion due to the stretching of the affected vessel that compromises blood flow at the ostium of the vessel.

Sudden death

- congenital coronary artery structural abnormalities such as stenosis, hypoplasia, or atresia. Such structural abnormalities of the coronary arteries interfere with normal myocardial perfusion. Sudden death also has been reported in association with high takeoff of coronary arteries. The latter may lead to impairment of diastolic coronary artery flow. Ventricular fibrillation has been identified as the terminal event in some patients with coronary artery anomaly who died suddenly during electrocardiographic monitoring.

Myocardial ischemia

- In addition to abnormalities mentioned under sudden death, myocardial ischemia also may occur in patients with anomalous origin of the left and, occasionally, right coronary artery from the pulmonary artery or right ventricle. In this type of anomaly, myocardial ischemia primarily occurs because of low coronary perfusion pressure secondary to the relatively low pulmonary diastolic pressure.

- Myocardial ischemia also may occur in the setting of a single coronary artery when the aberrantly coursing vessel terminates prematurely and the myocardium distal to the vessel is inadequately perfused.
- Intramyocardial course of coronary arteries (ie, myocardial bridge) occasionally has been associated with myocardial ischemia. The mechanism of myocardial ischemia in this condition is not fully elucidated.
- Large coronary artery fistulas also may reduce myocardial perfusion and, thus, cause ischemia

Congestive heart failure

- Large coronary artery fistulas may result in right- or left-sided cardiac volume overload with or without symptoms of congestive heart failure.
- Drainage into the right heart produces right-to-left shunt with dilation of the right heart chambers and increase in pulmonary resistance.

- Heart failure also may be the predominant presentation in infants with the origin of the left main coronary artery from the pulmonary trunk. the left ventricle appears dilated and globally hypokinetic on transthoracic echocardiography.