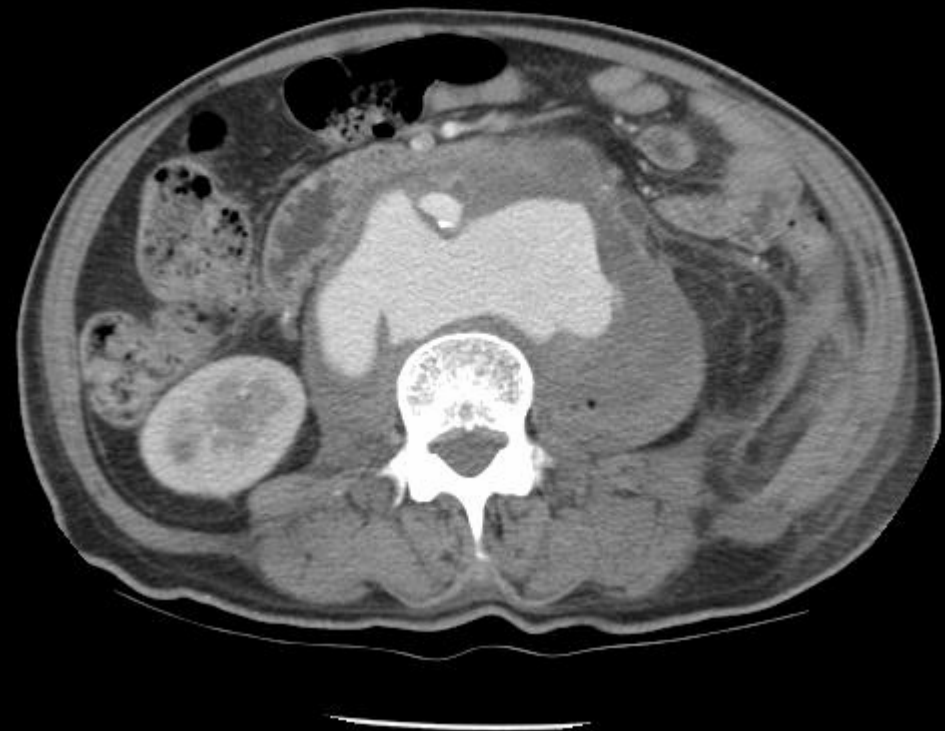

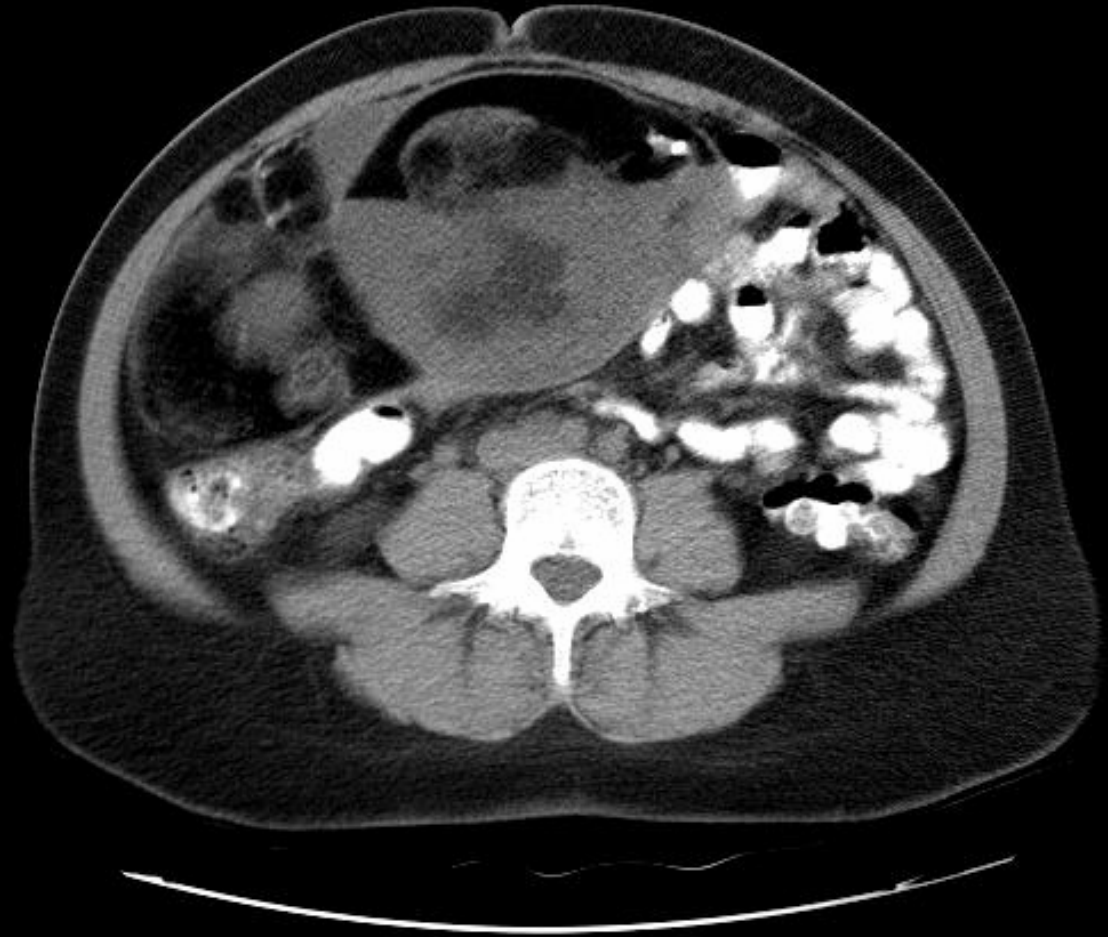
# CT scan Cases

- An 60-year-old male, complaining of fever and abdominal pain
- What's the diagnosis?



**Mycotic aneurysm**

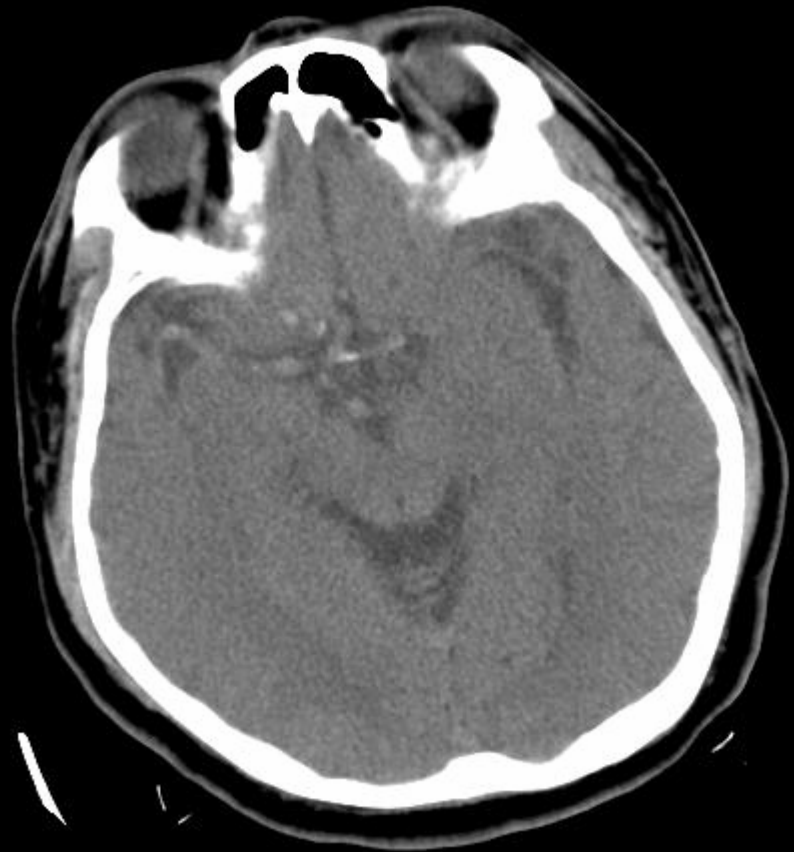
- LMD referral for incidental pelvic mass
- What's the diagnosis?



**Dermoid cyst**

- Man with arm and leg weakness
- Questions:
  1. Which arm and which leg?
  2. Diagnosis?

詳見下頁

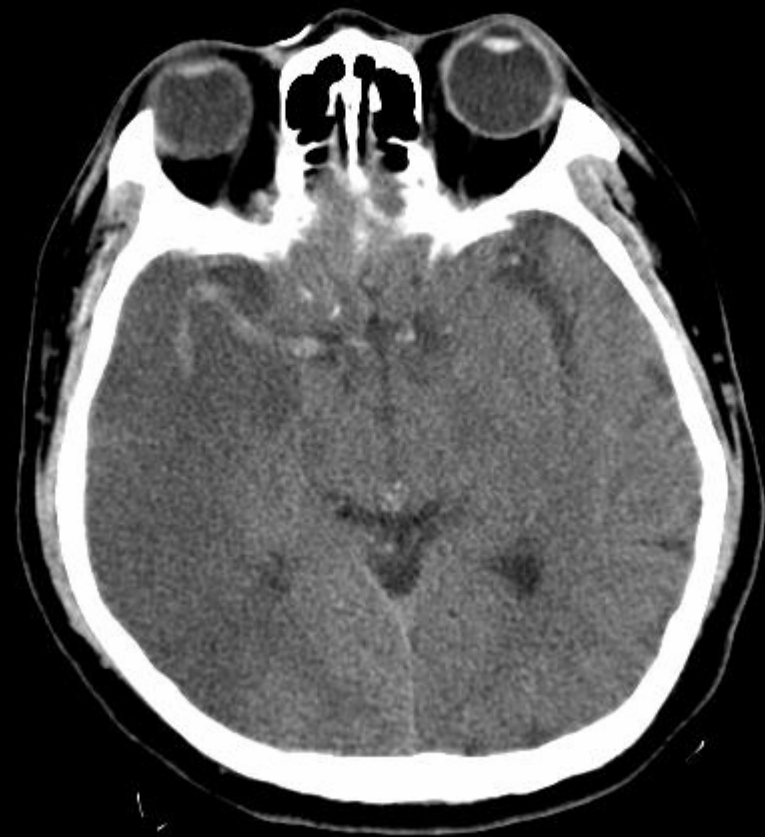

**Left arm and leg**

**Right MCA infarction**

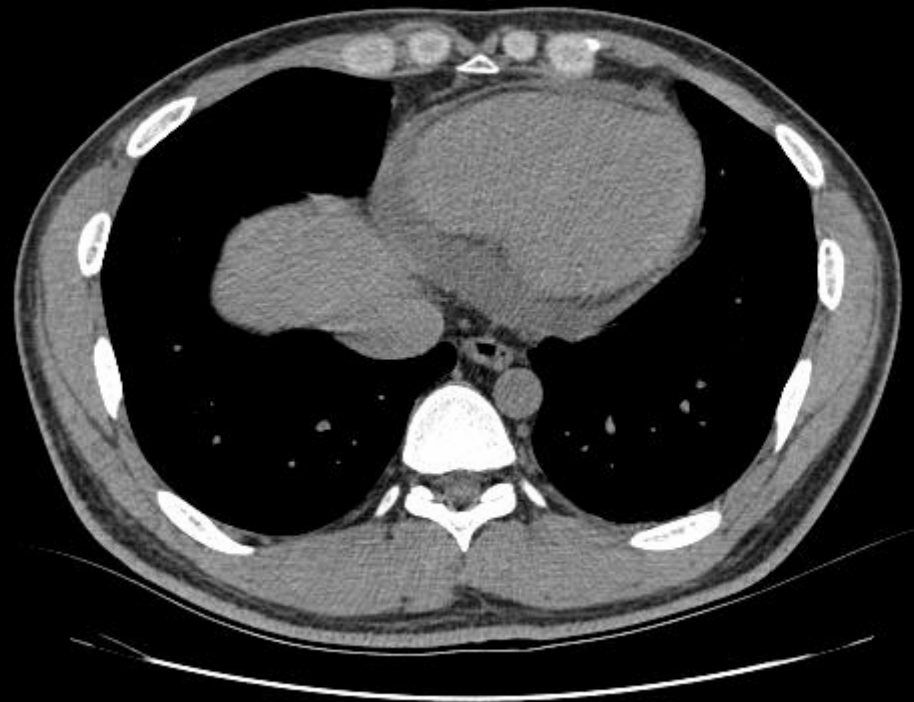
**–Dense MCA sign**

**–Figure on the left:  
2 days later**



- 75-year-old male with shortness of breath

- What's the finding in this film?

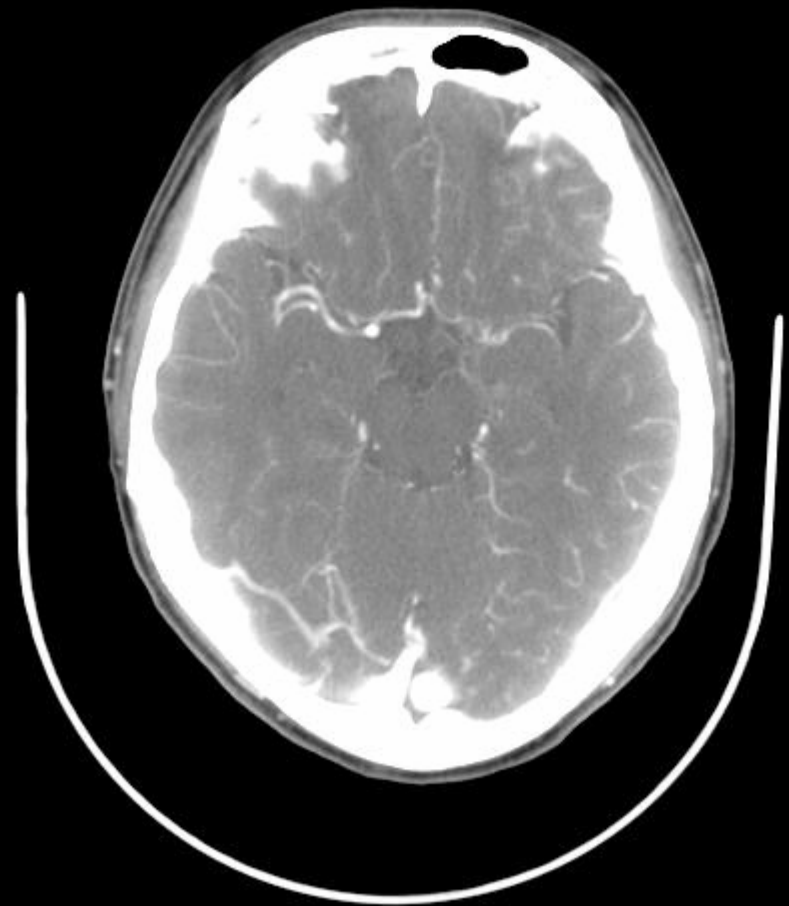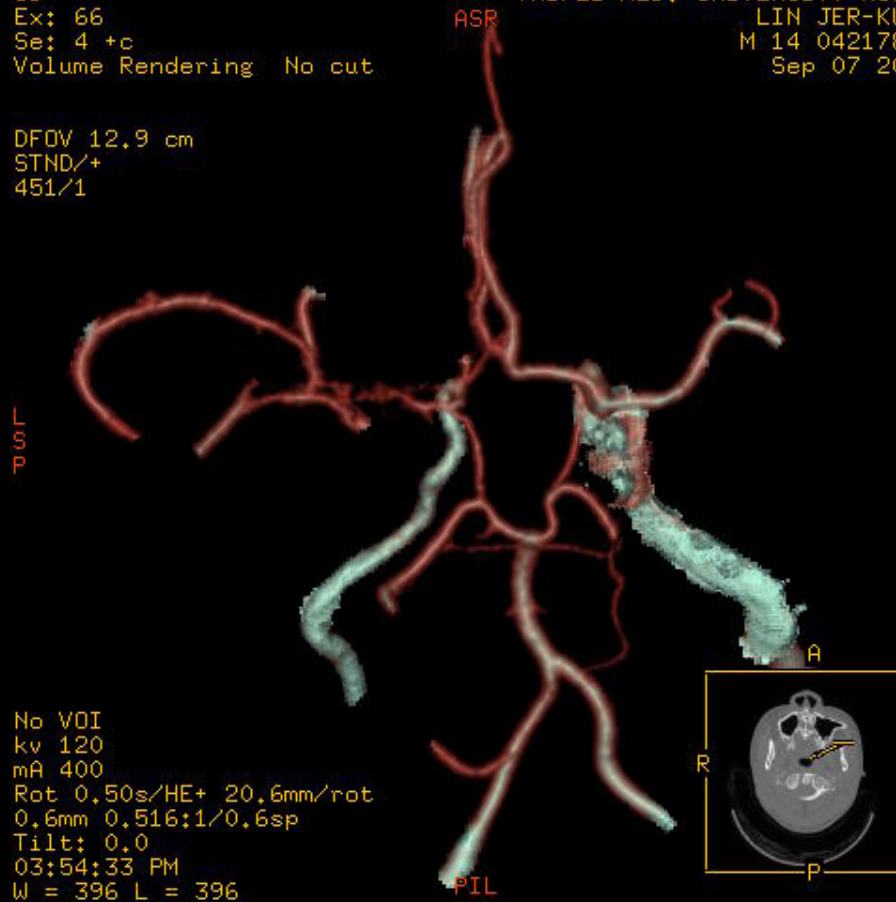


- **Pericardial effusion**

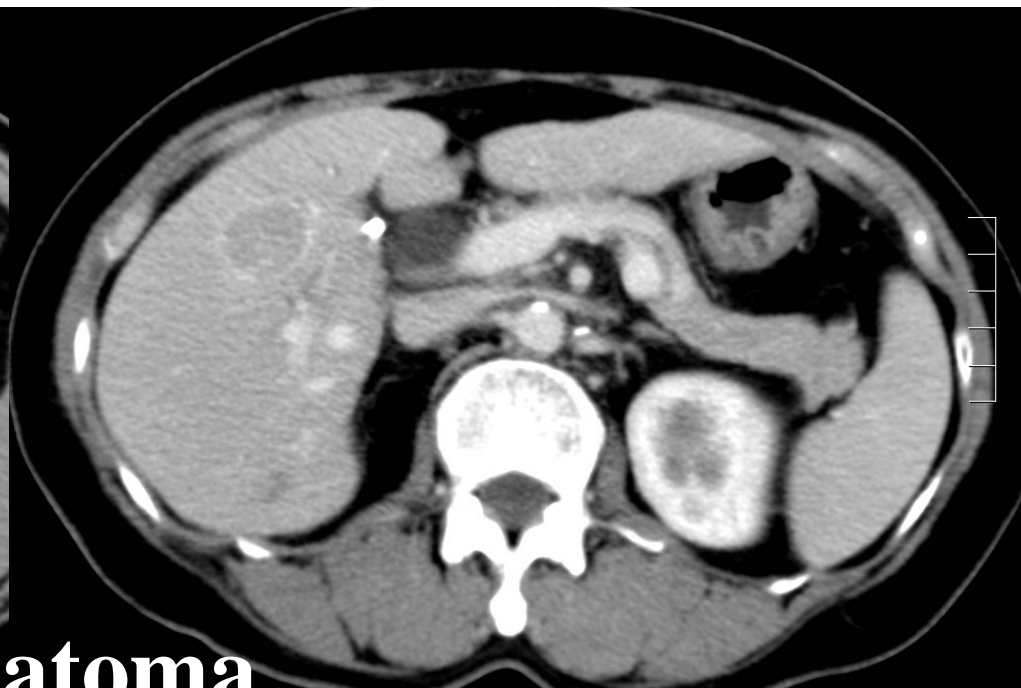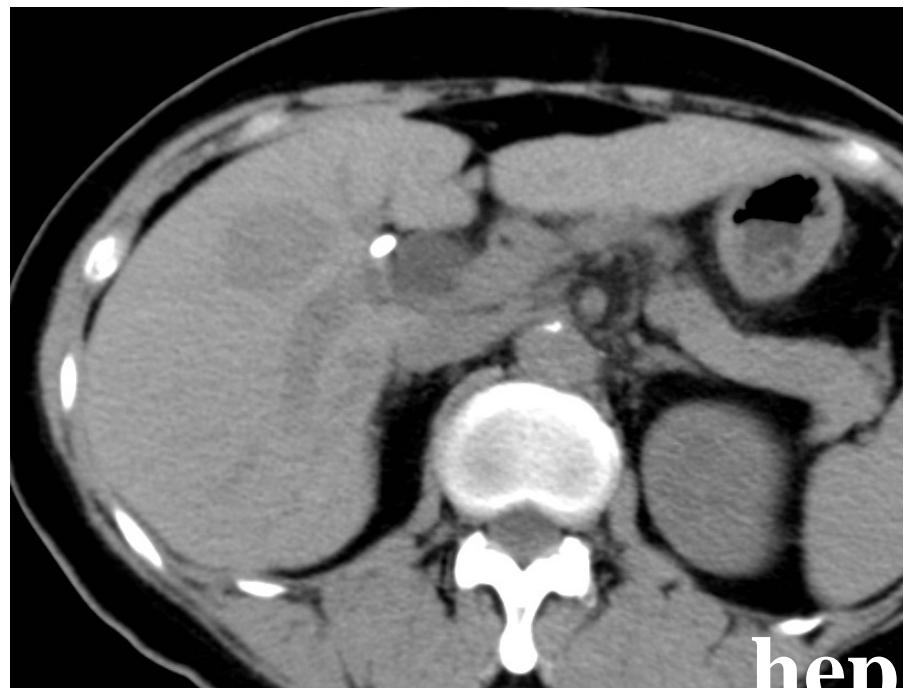
3D  
Ex: 66  
Se: 4 +c  
Volume Rendering No cut

DFOV 12.9 cm  
STND/+  
451/1

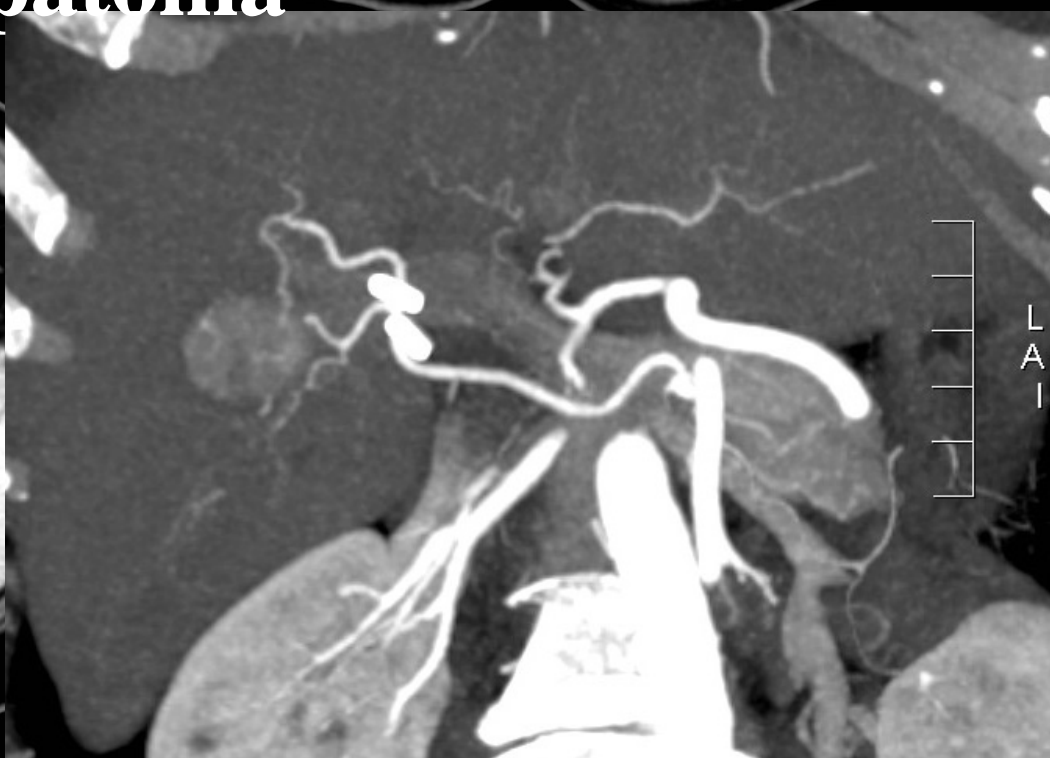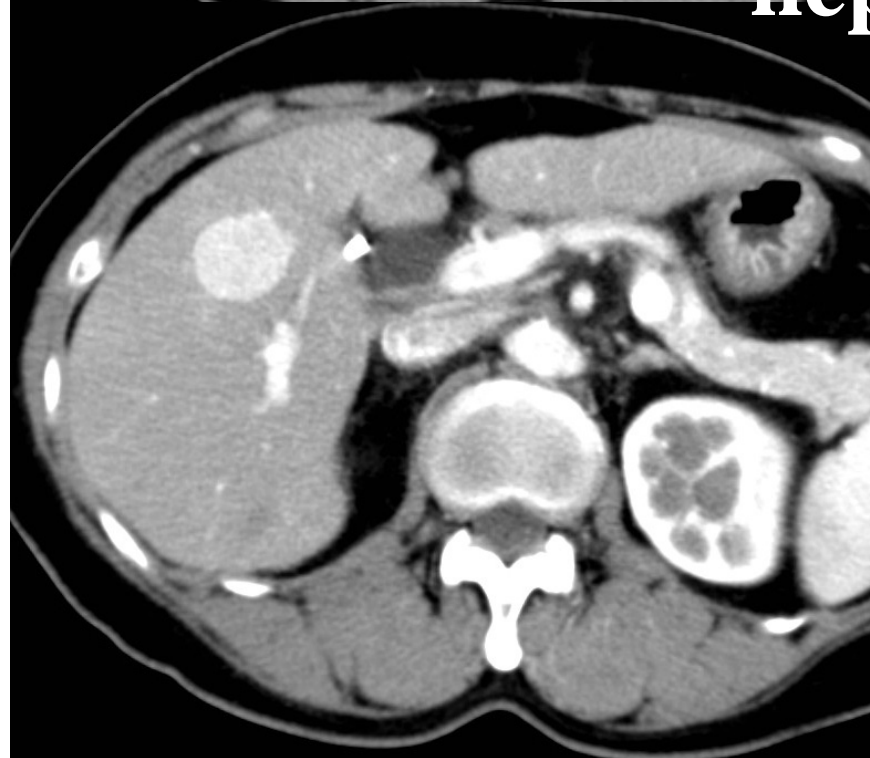TAIPEI MED. UNIVERSITY Hos  
LIN JER-KU  
M 14 042178  
Sep 07 20

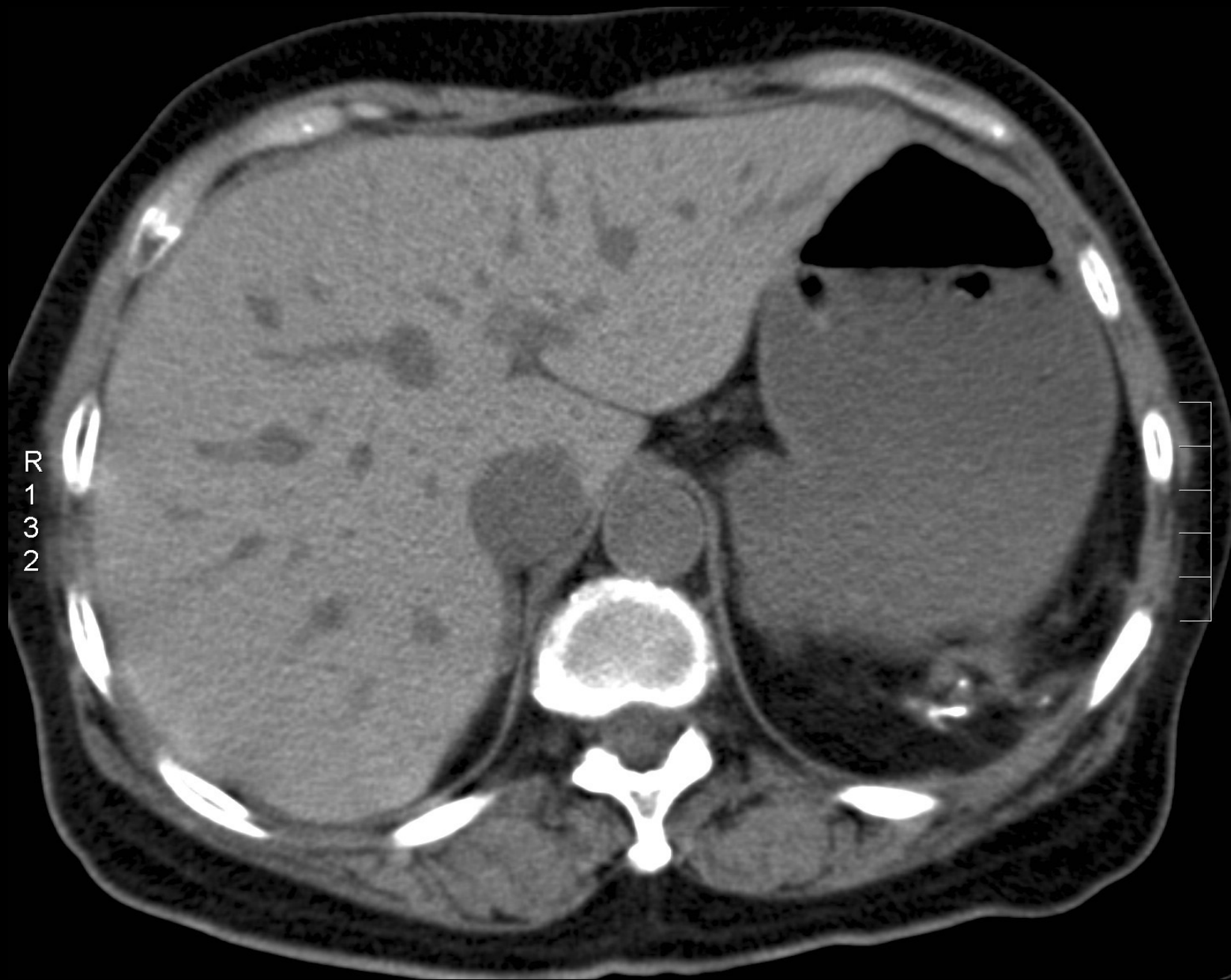

# Moyomoya disease

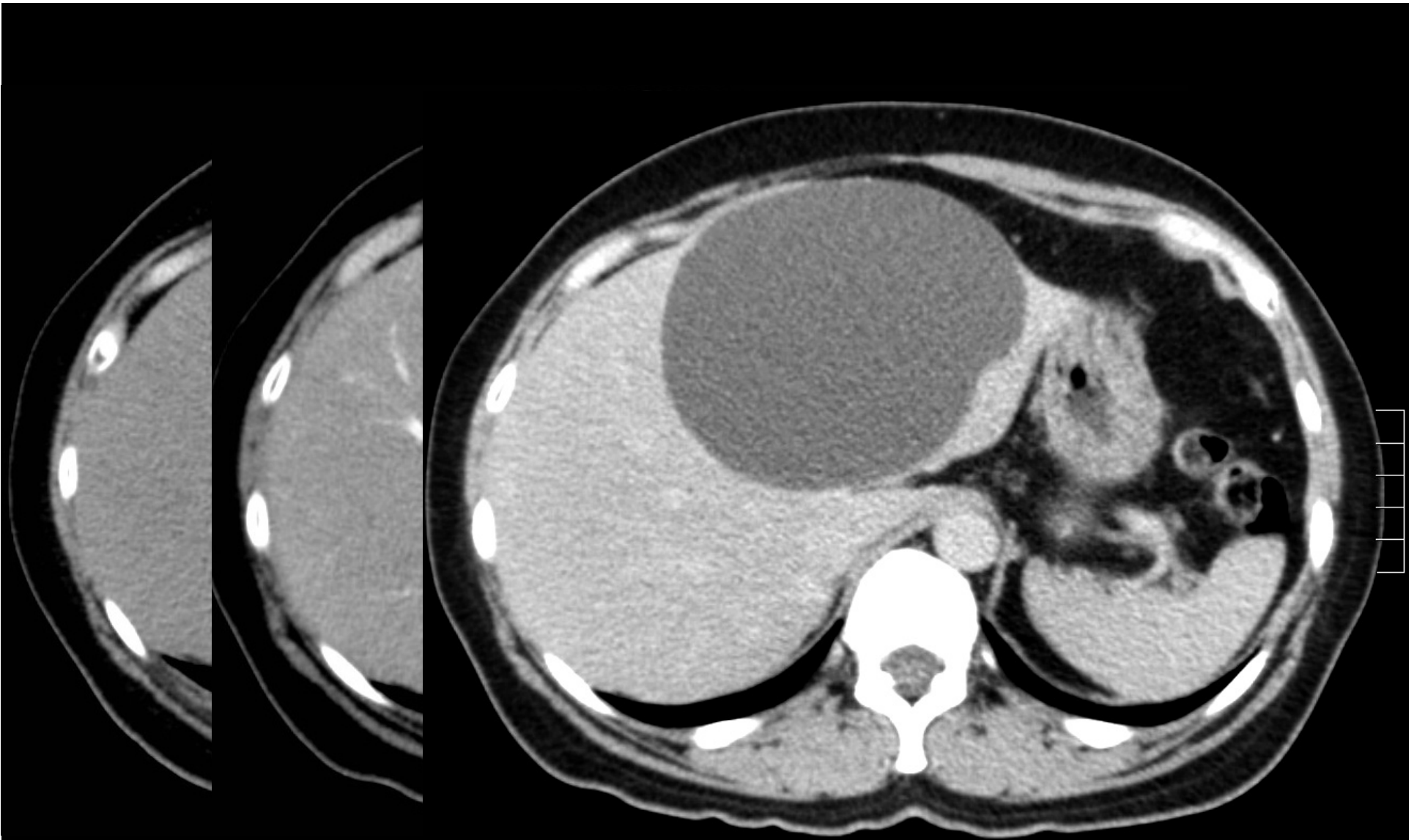

hepatoma

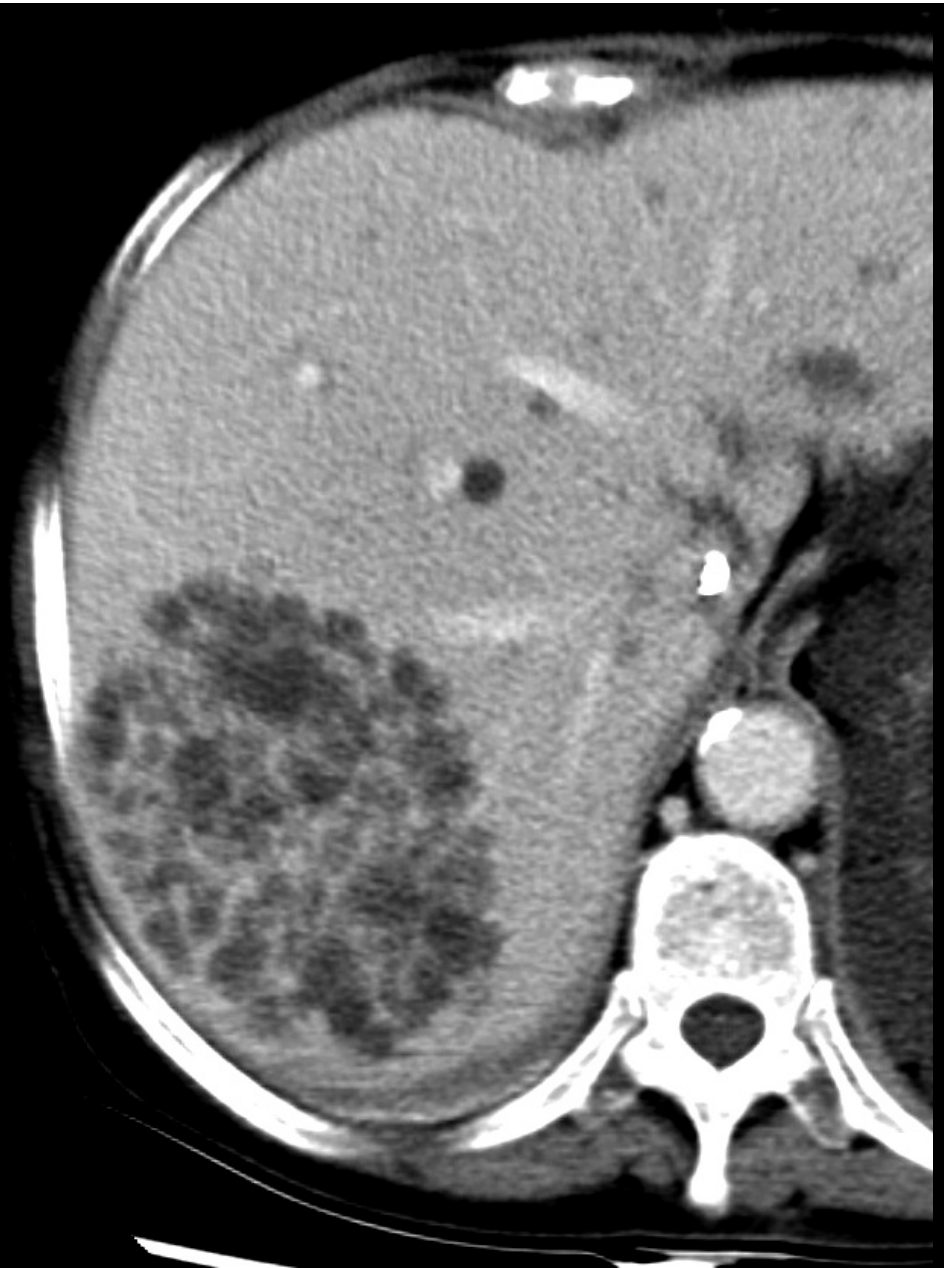
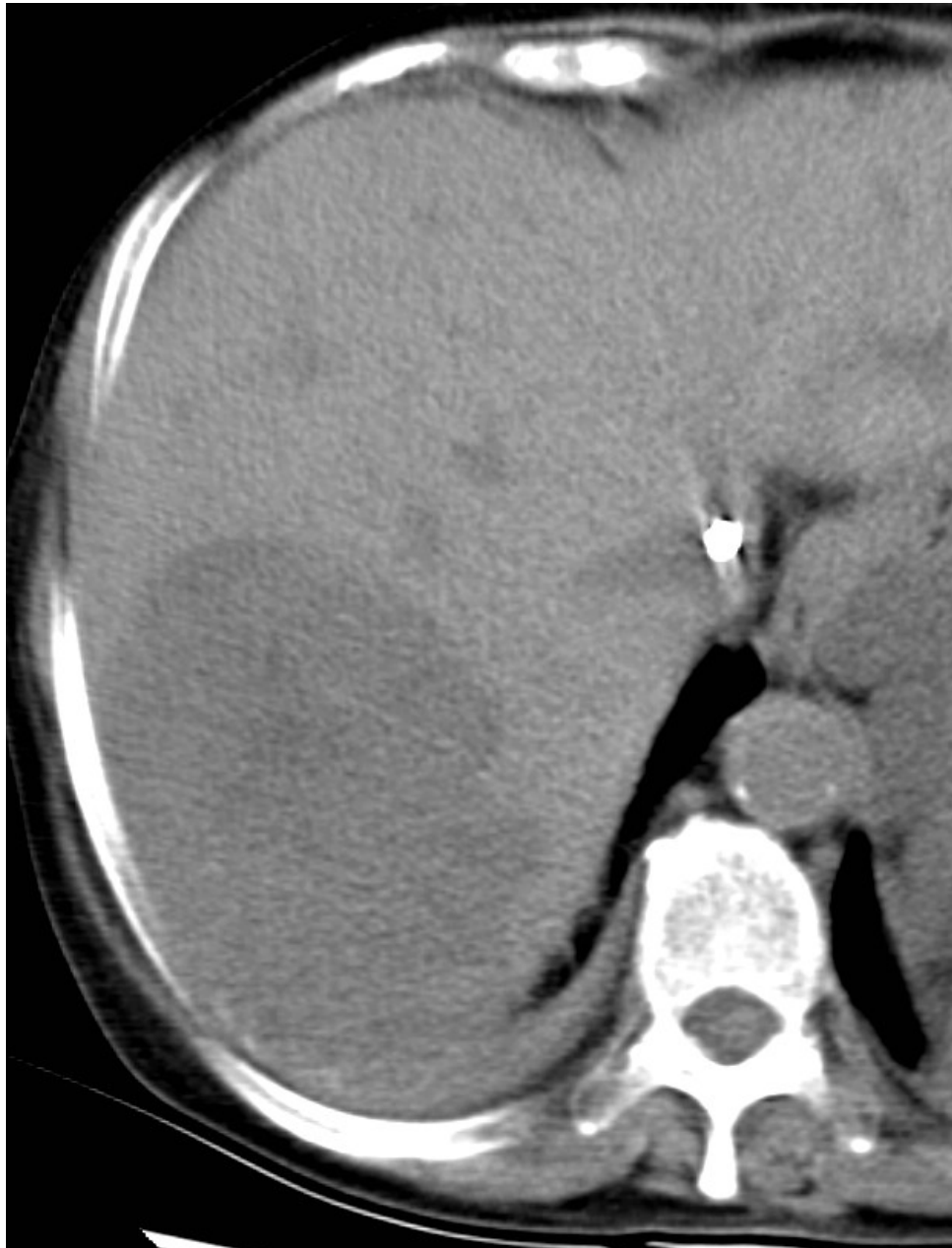


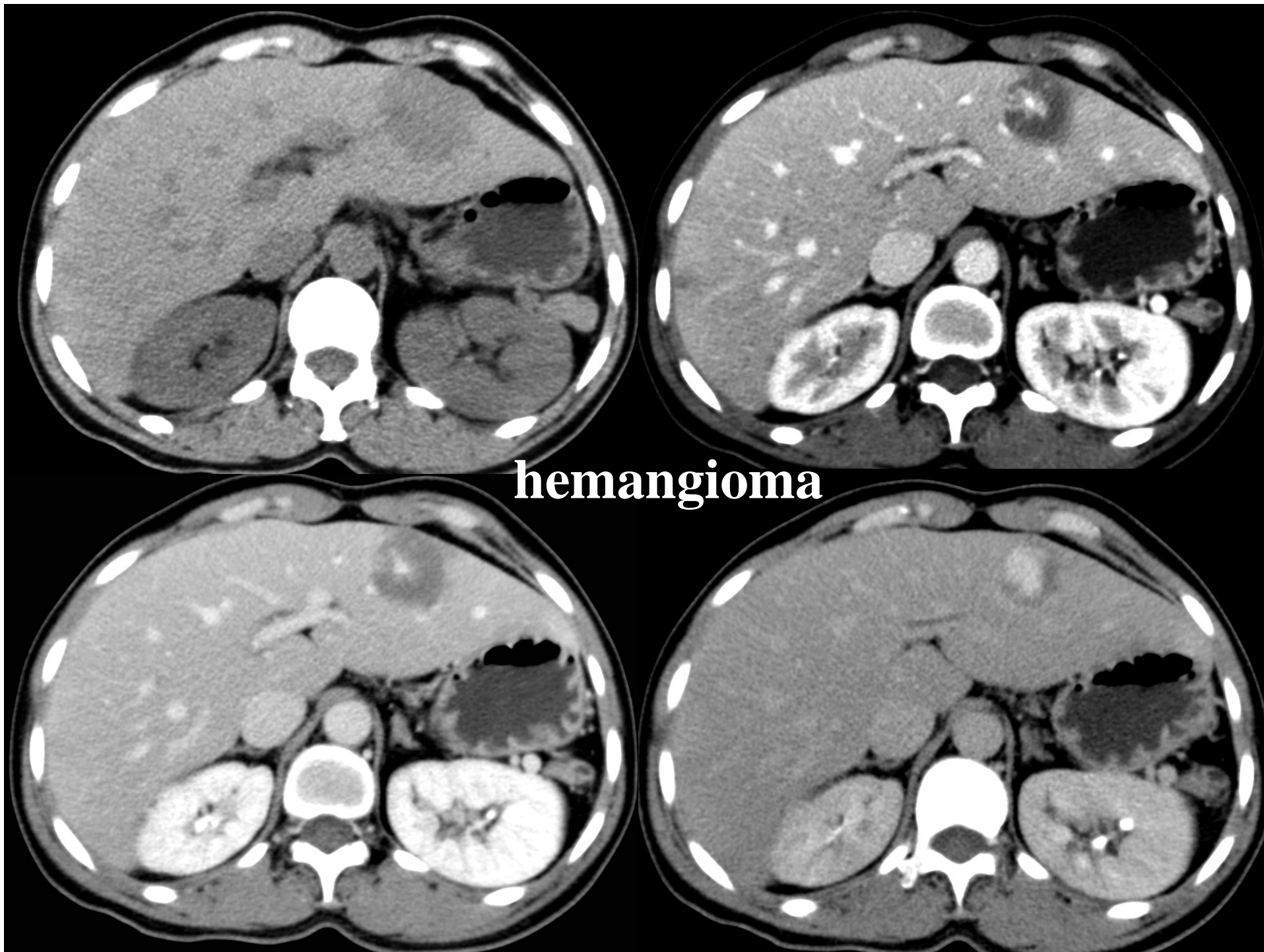
**Iron overload**

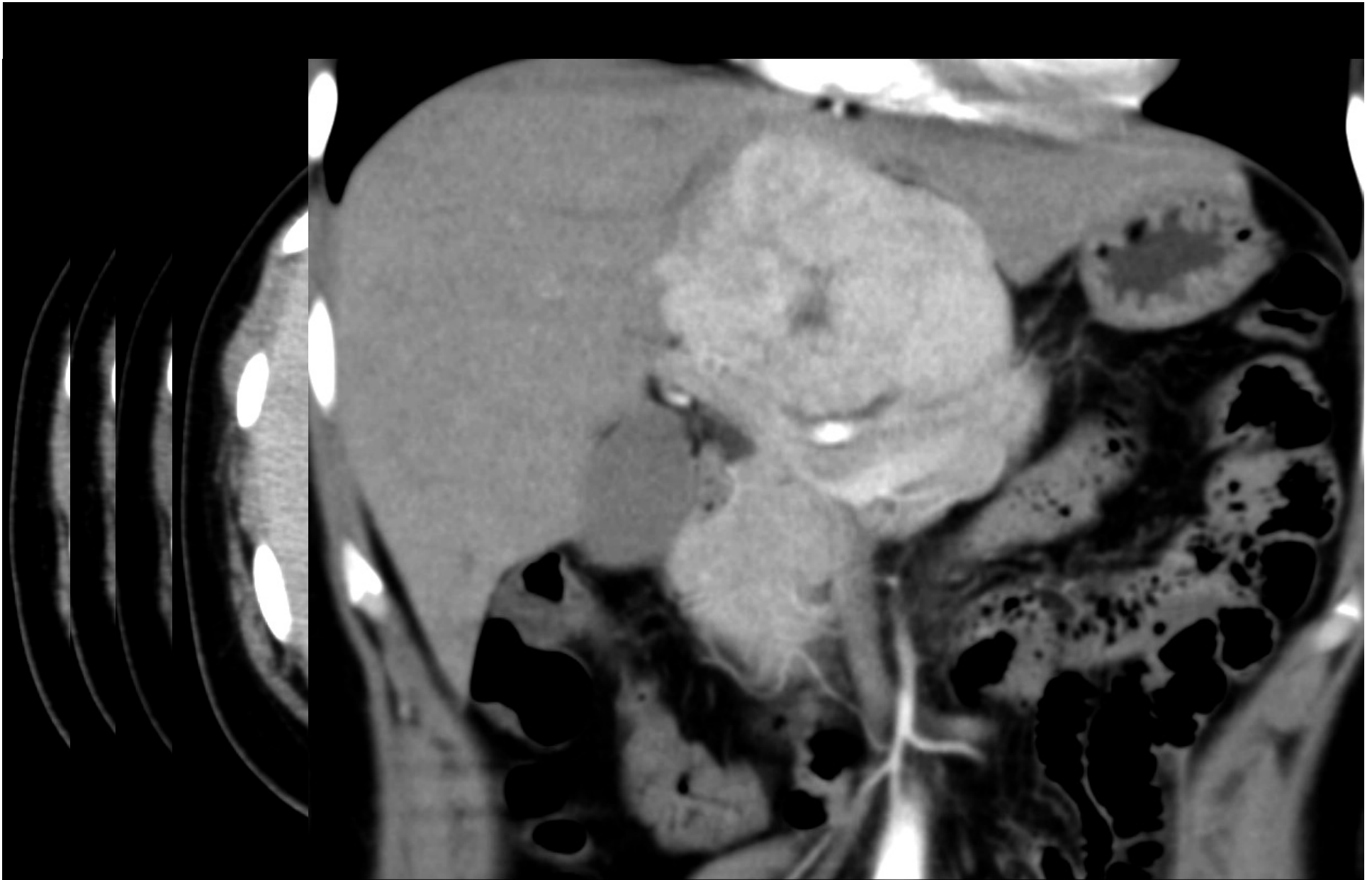


**Simple huge hepatic cyst**



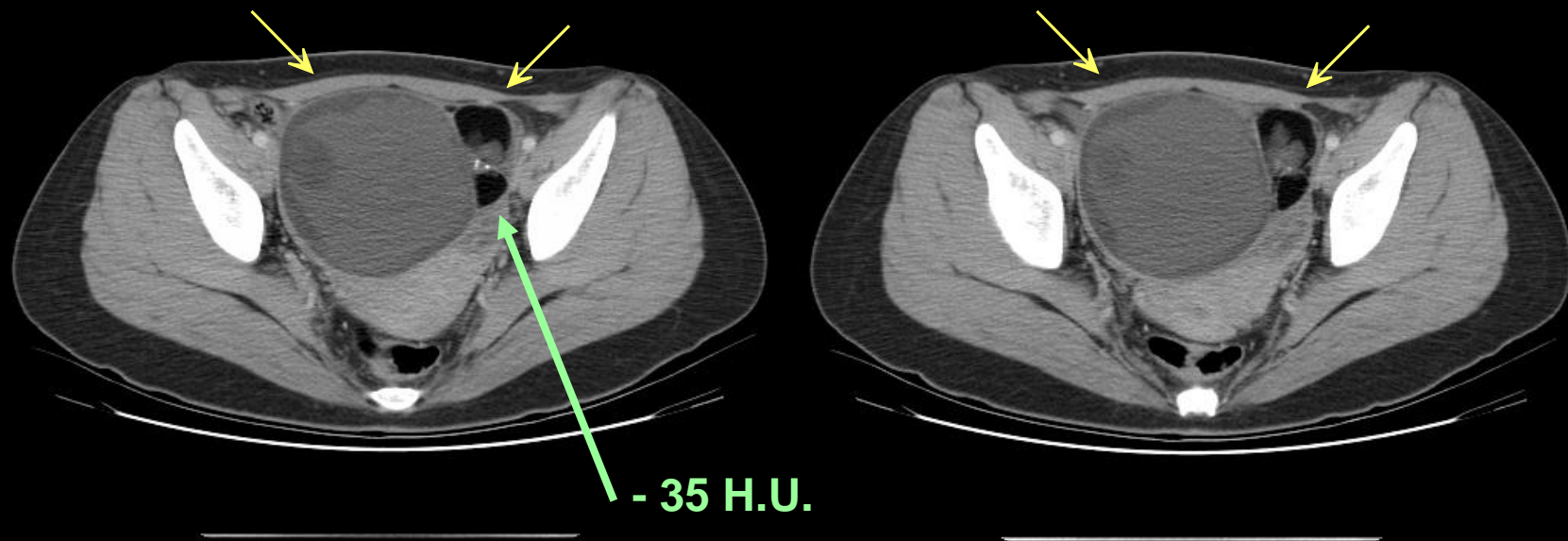
**Pyrogenic abscess**



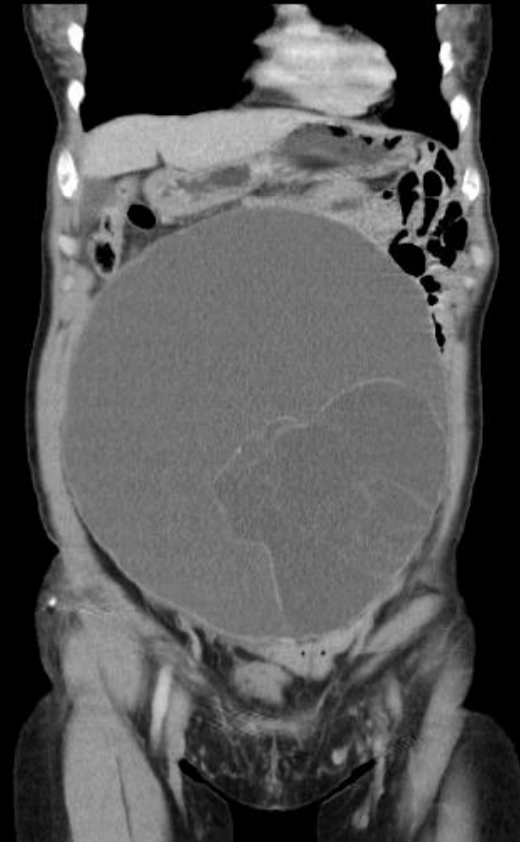
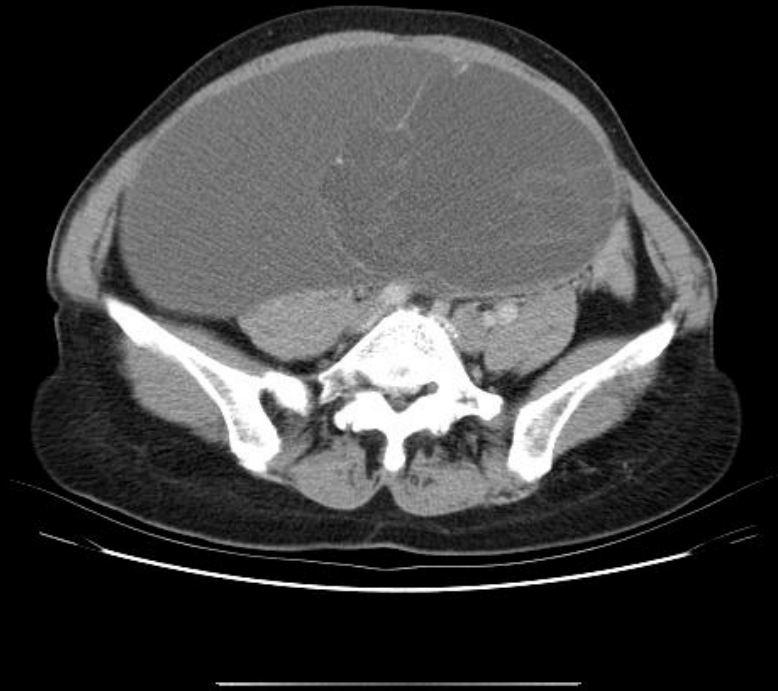


**Focal nodular hyperplasia**

# (ovarian) (mature cystic) teratoma



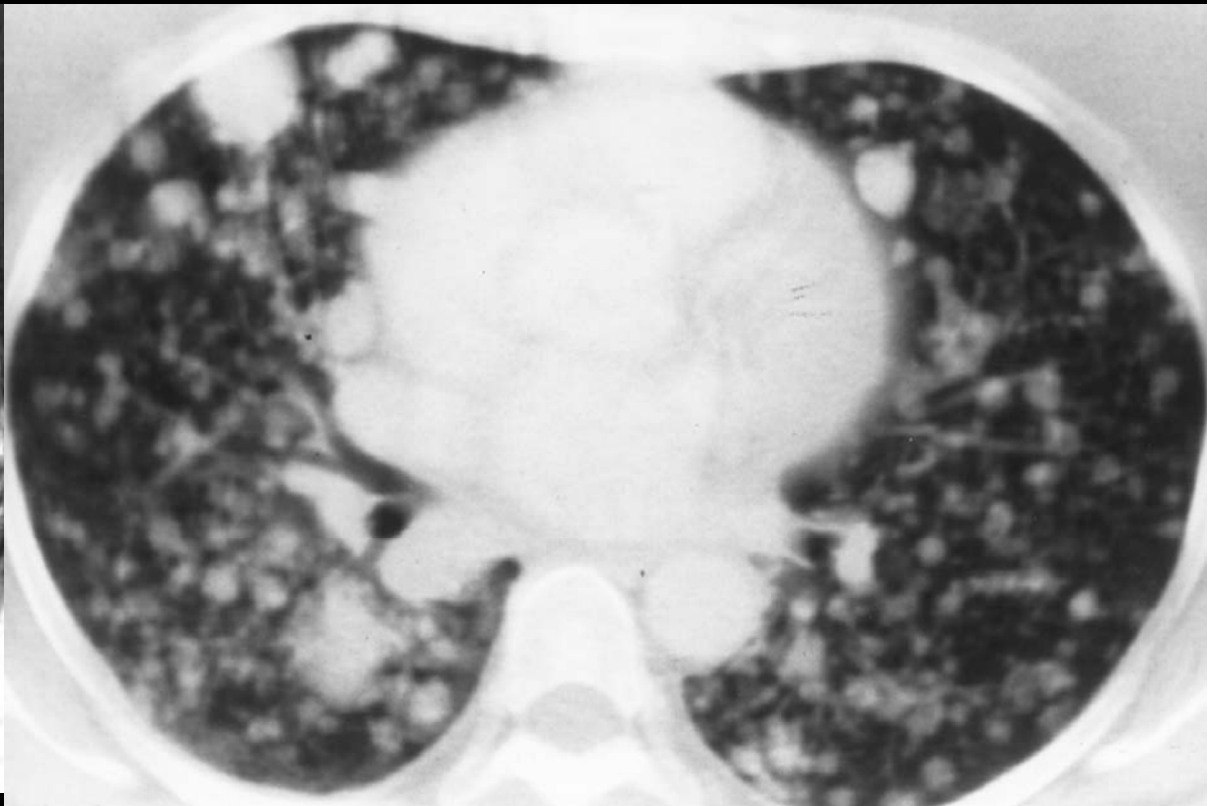
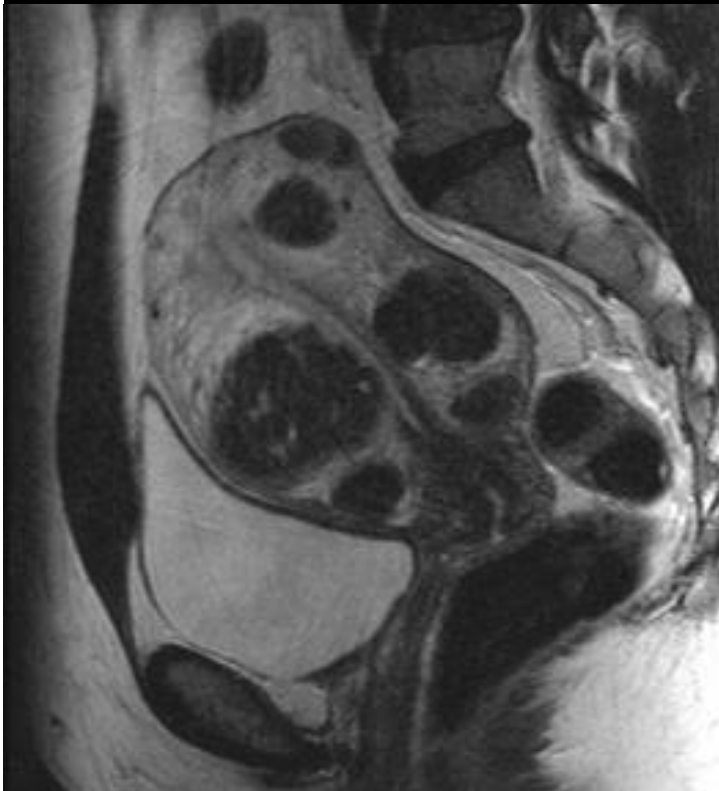# **(ovarian) mucinous cystadenoma**



# Benign metastasizing leiomyoma(tosis)

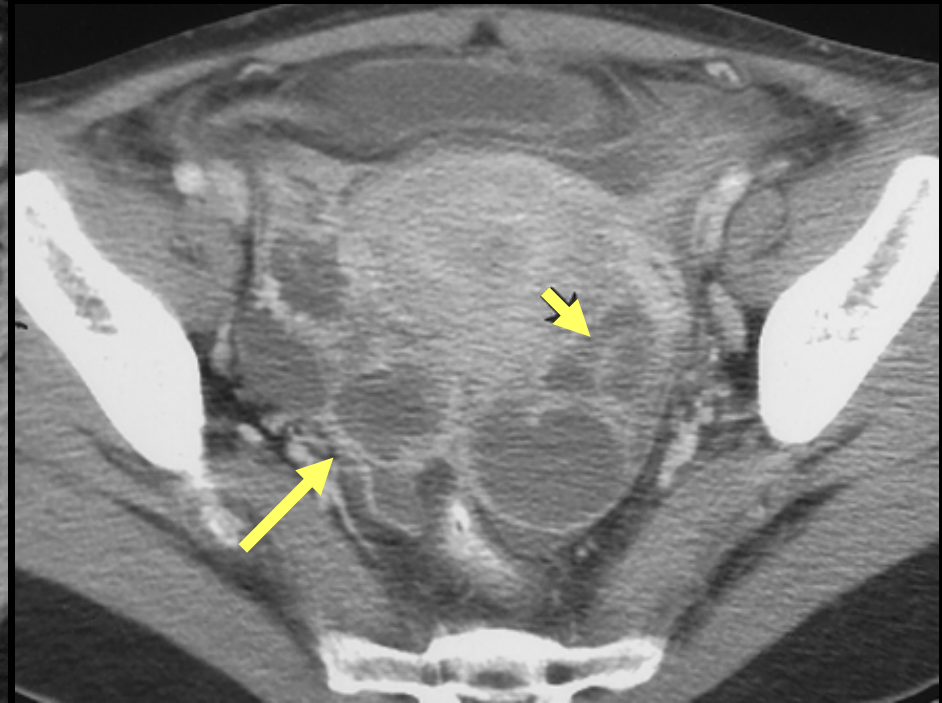
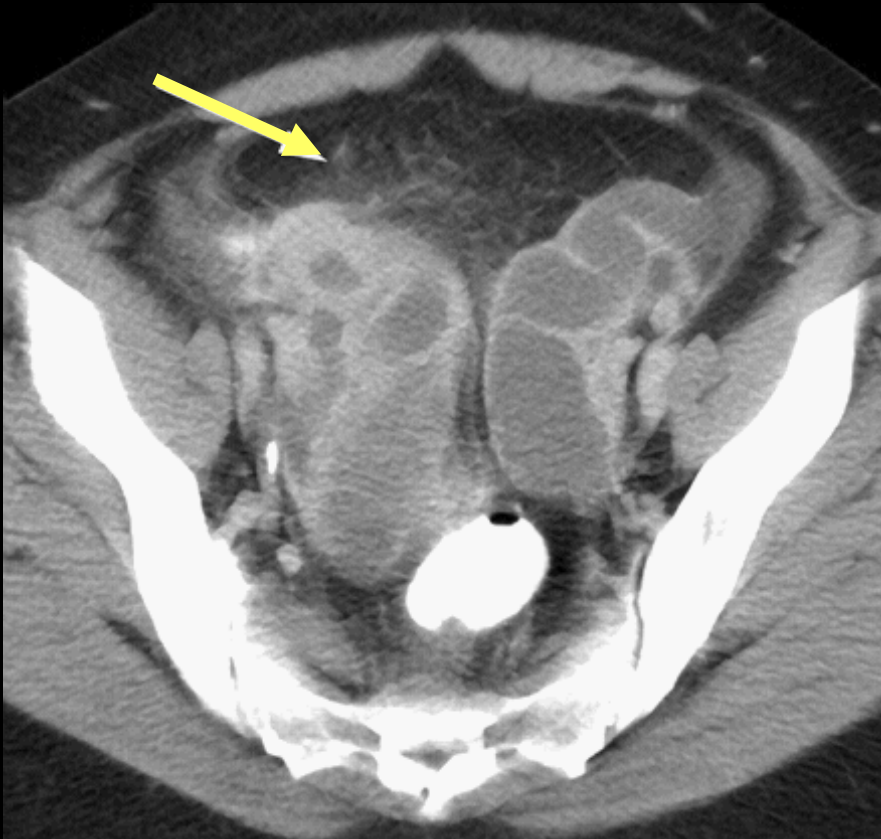History of uterine leiomyomas

@ 請寫 lung 的 finding



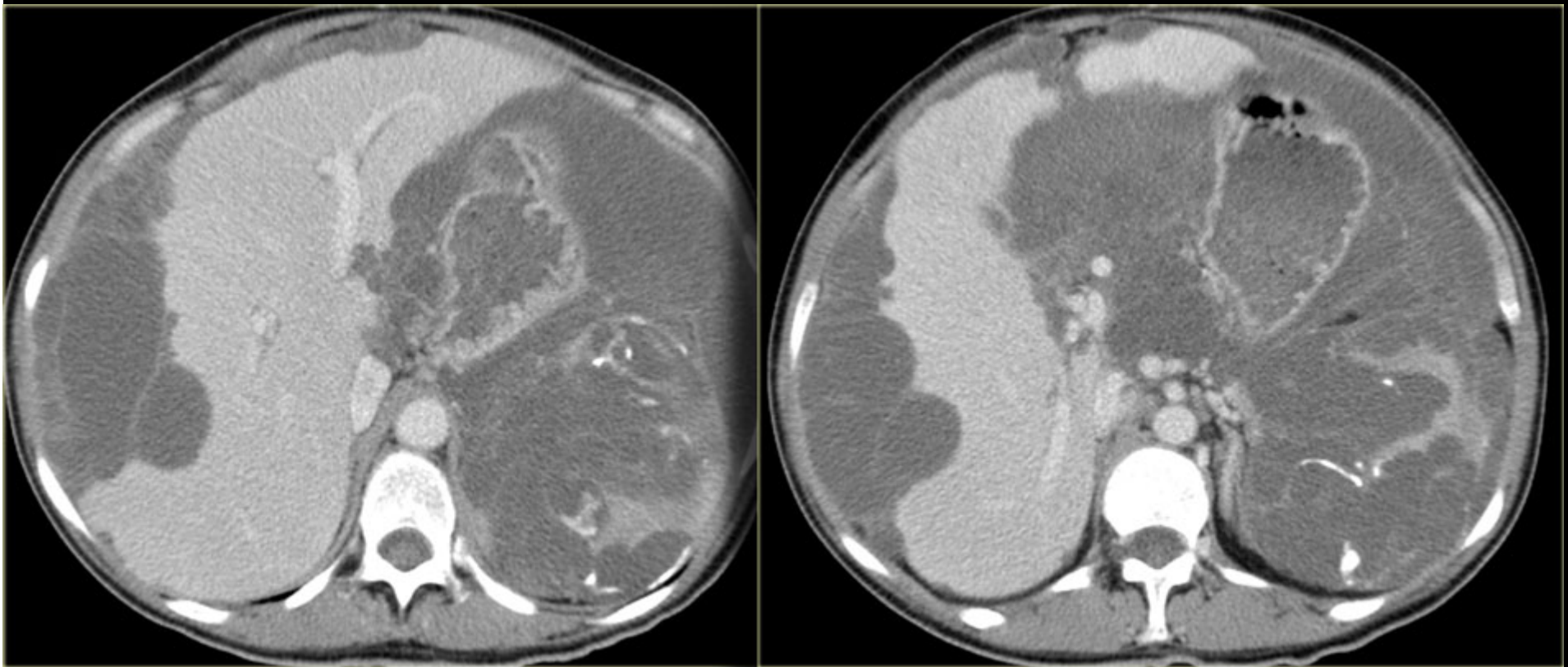
# Tubo-ovarian abscess

History of fever & low abdominal pain

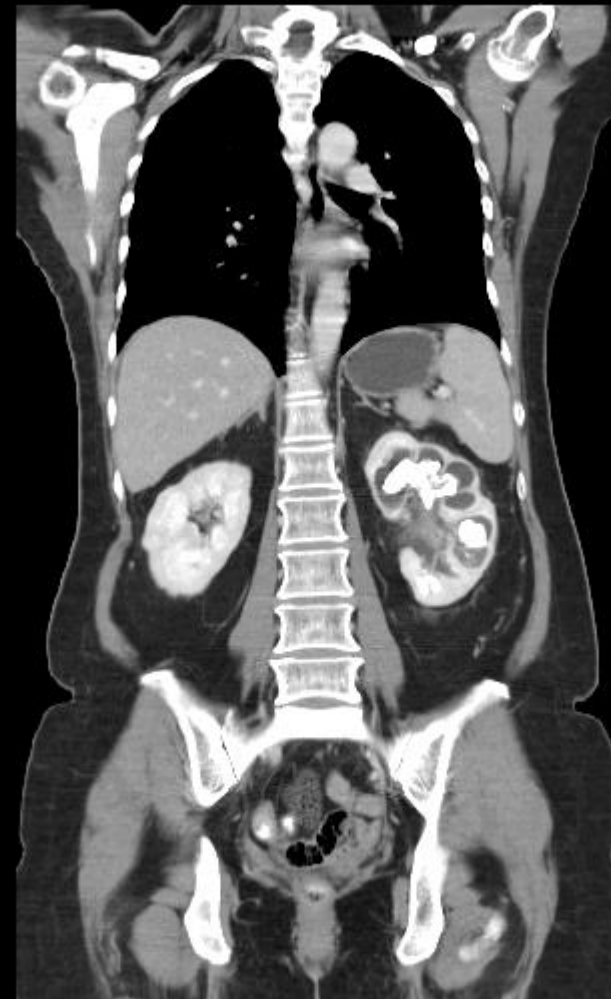
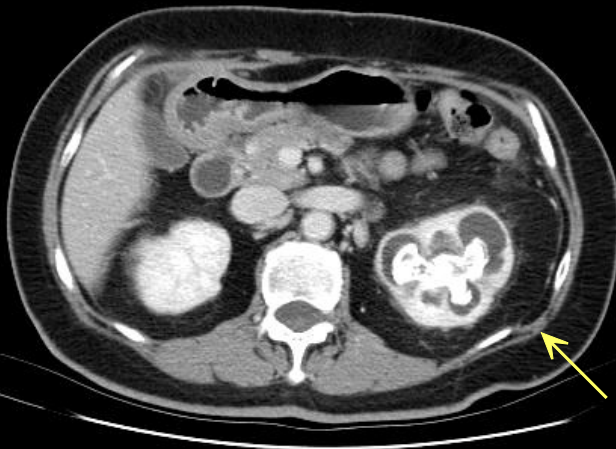
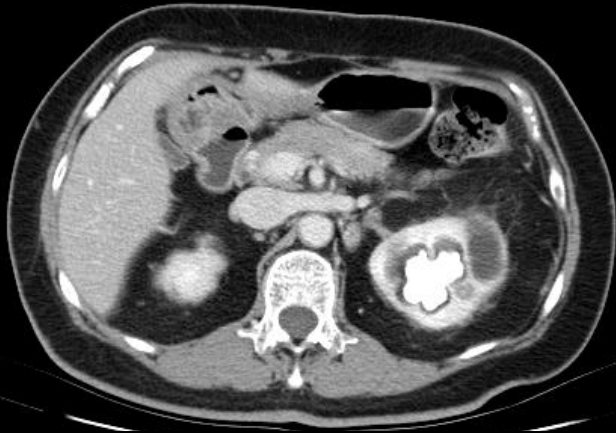
# Pseudomyxoma peritonei

History of ovarian mucinous cystadenocarcinoma

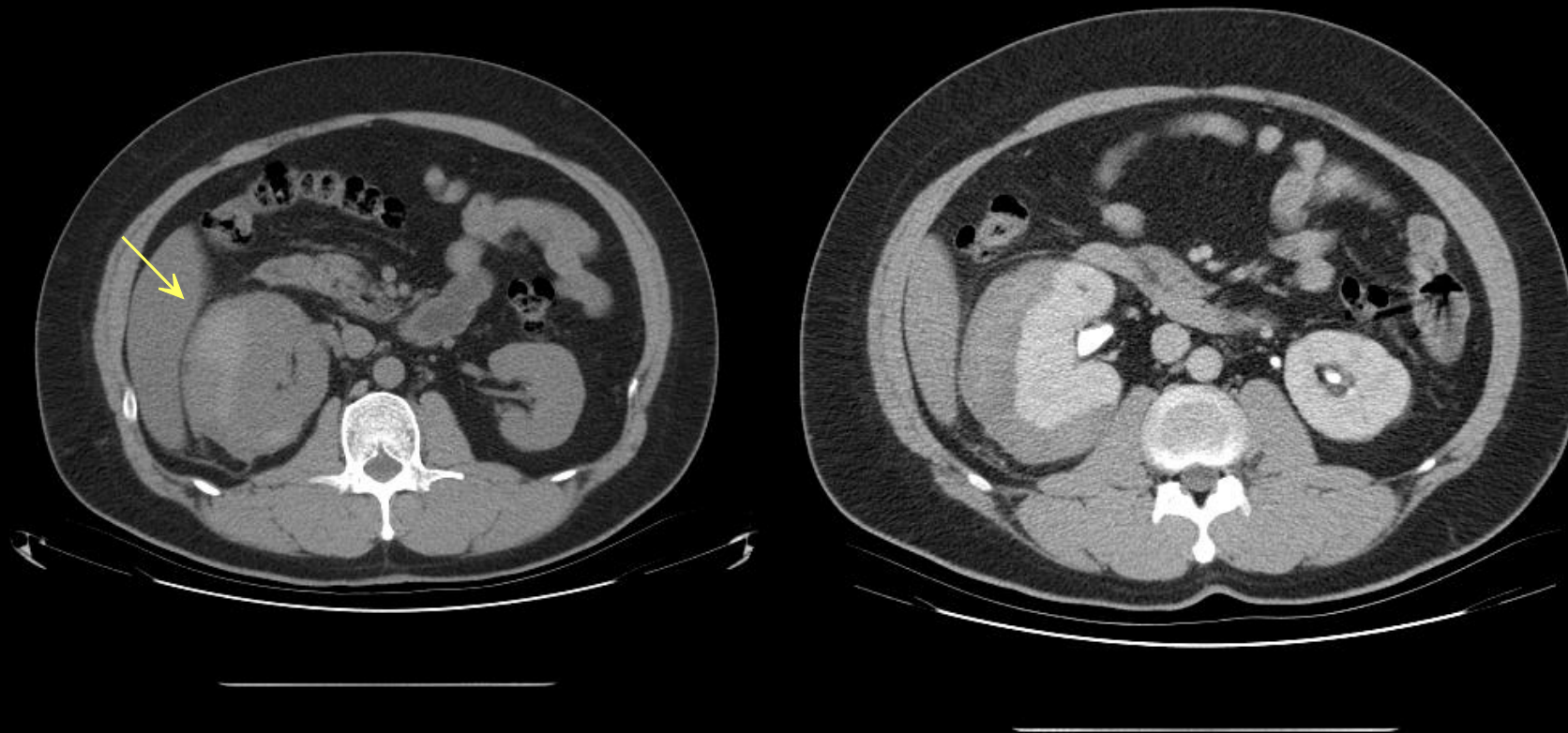

# **(left renal) staghorn stone**



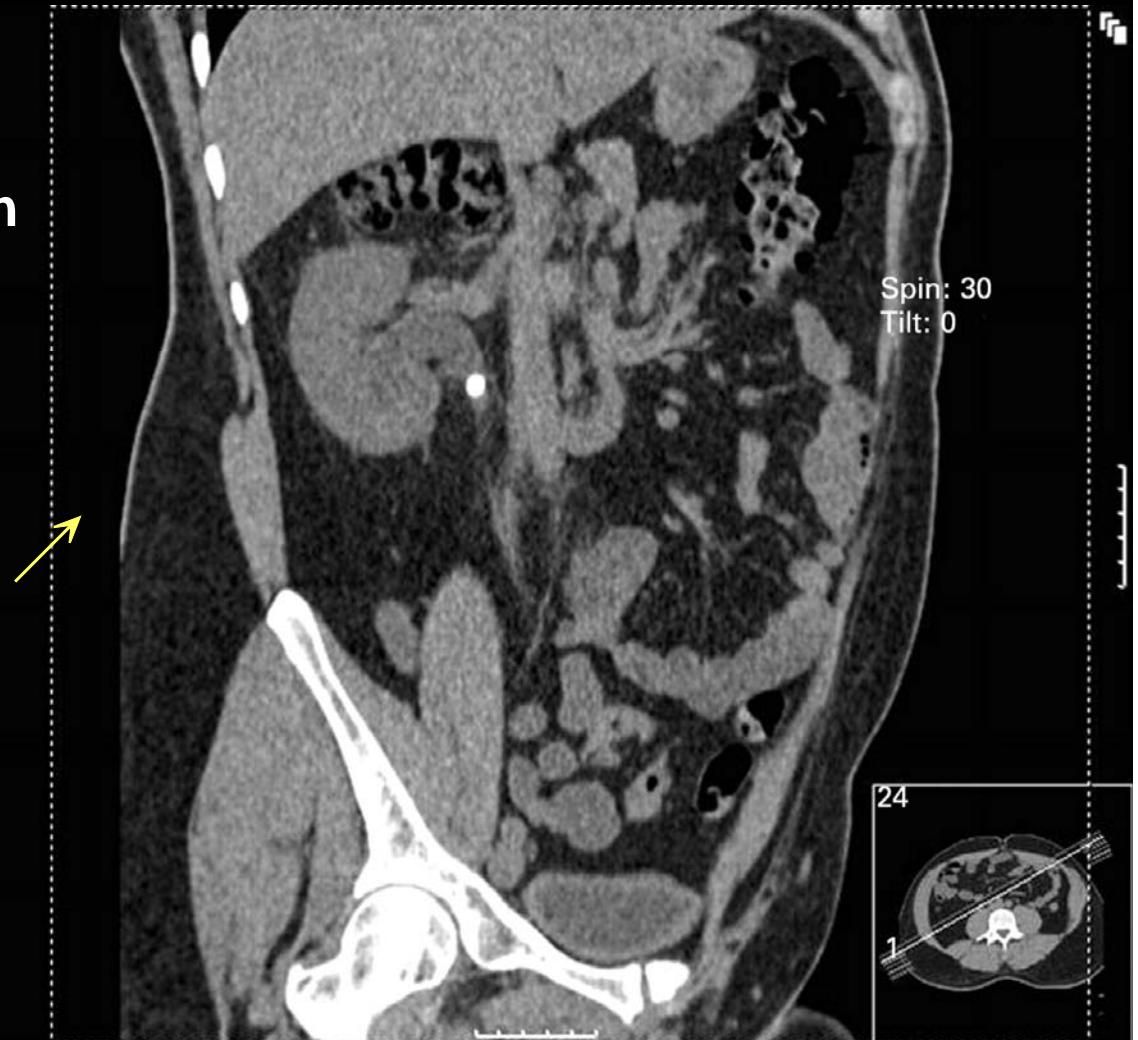
# (right renal) subcapsular hematoma

History of trauma



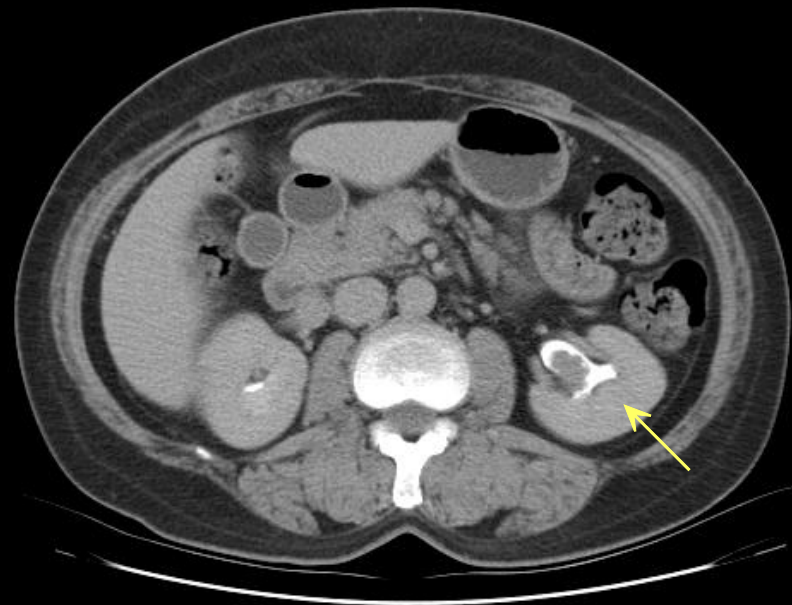
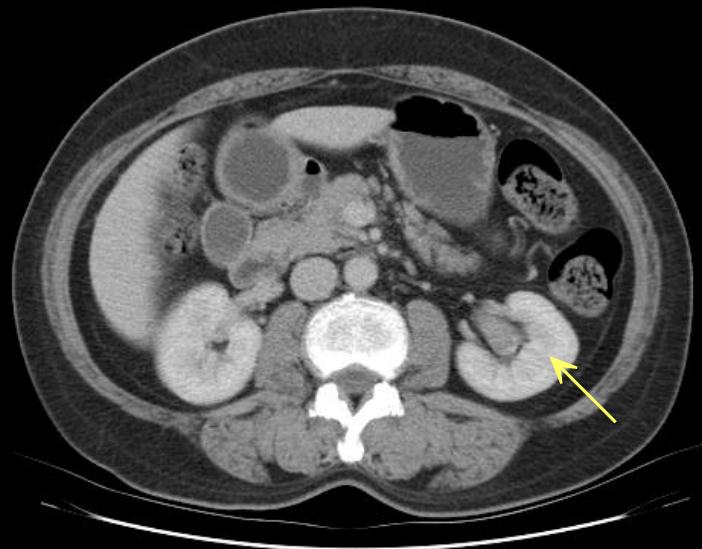
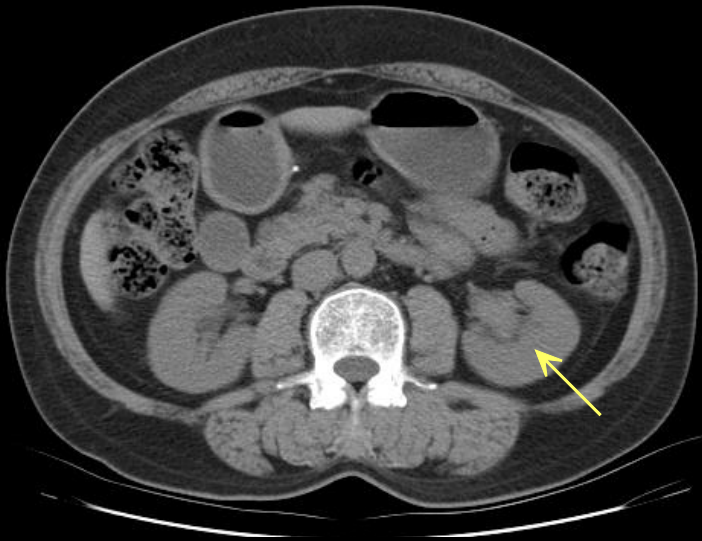
# Right ureteral stone (with hydronephrosis)

History of right abdominal pain

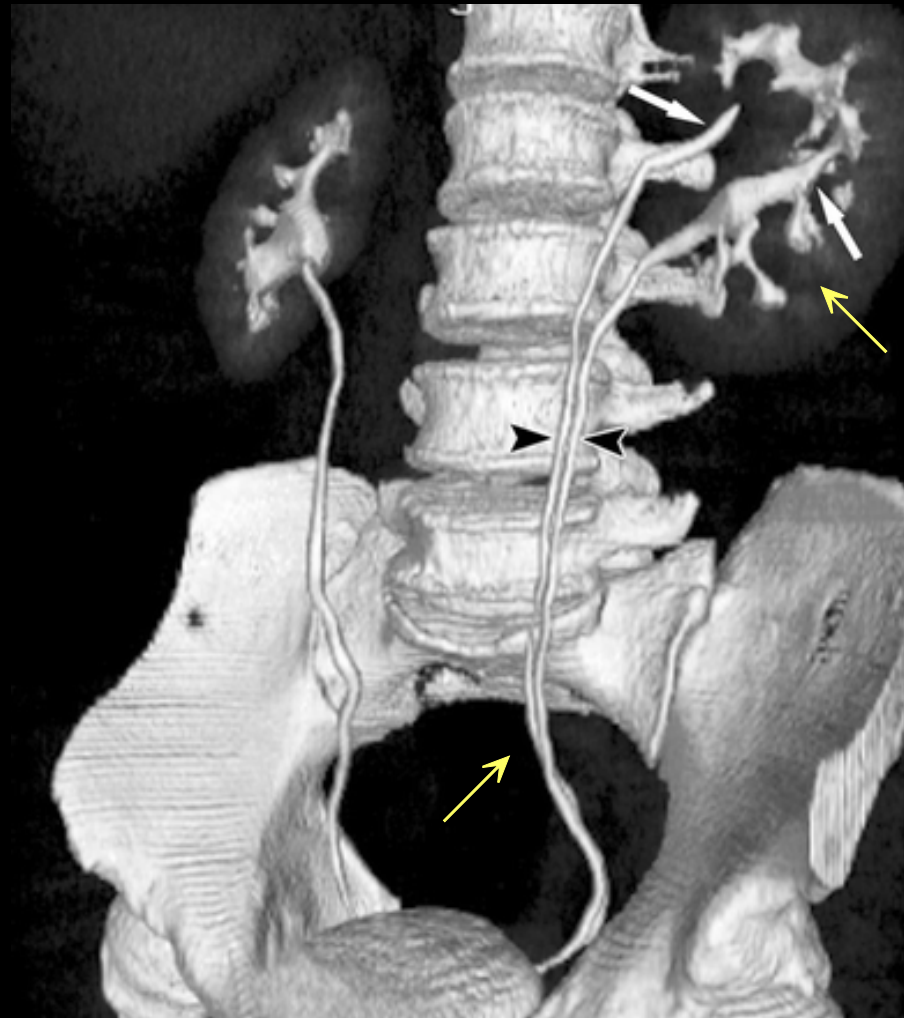


# Left renal pelvis TCC (urothelial cancer)

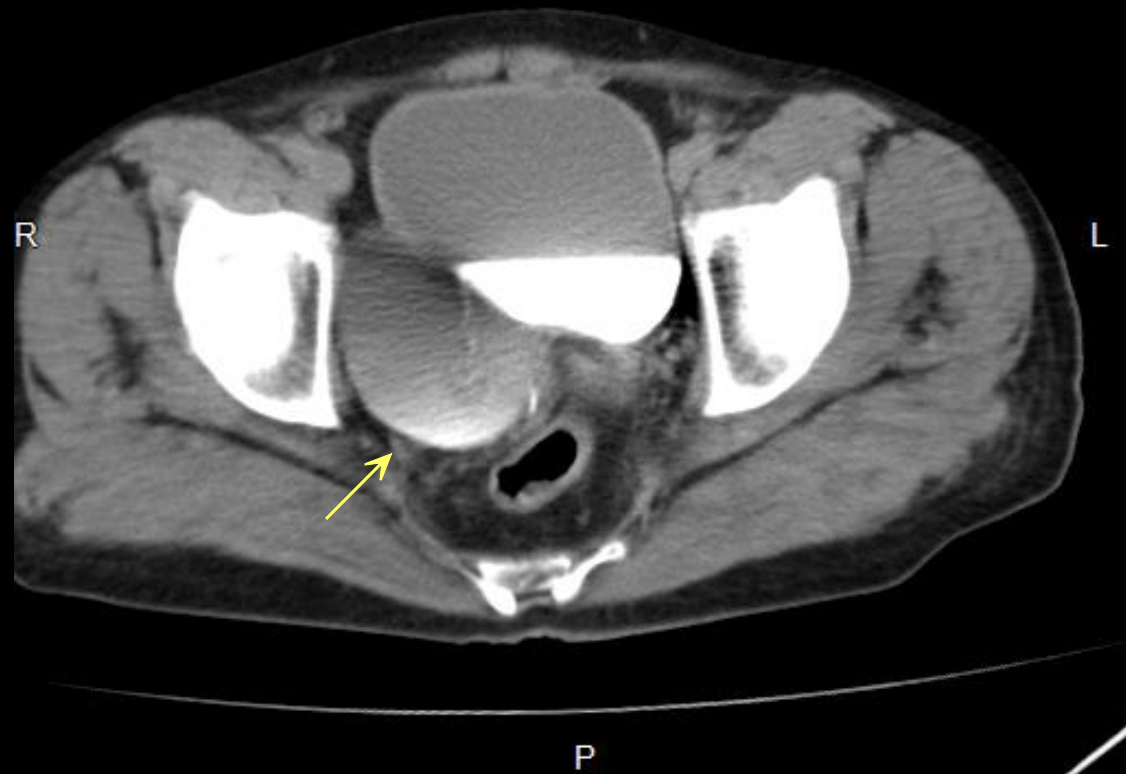
History of gross hematuria



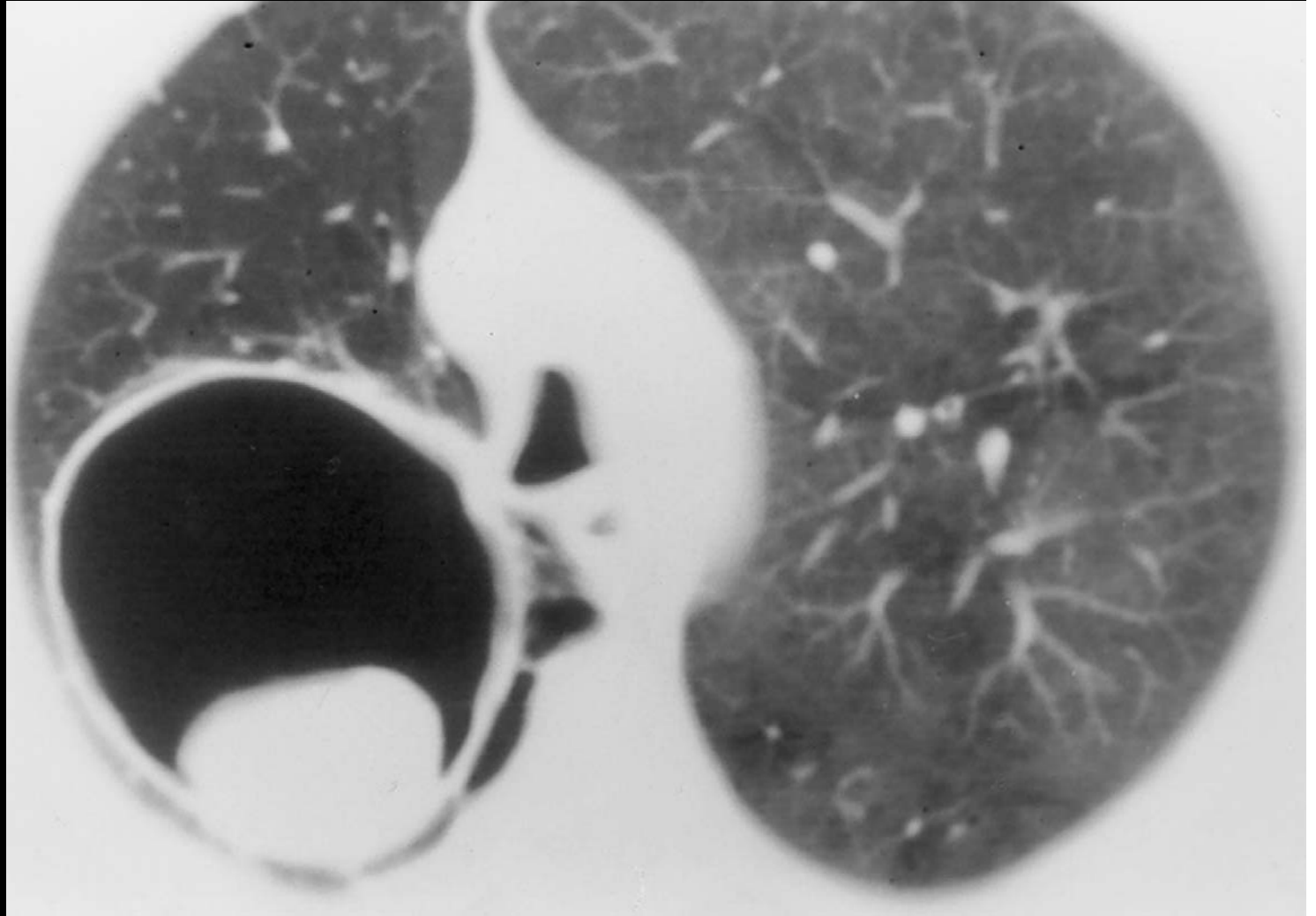
# Left renal and ureteral duplication



# Urinary bladder diverticulum

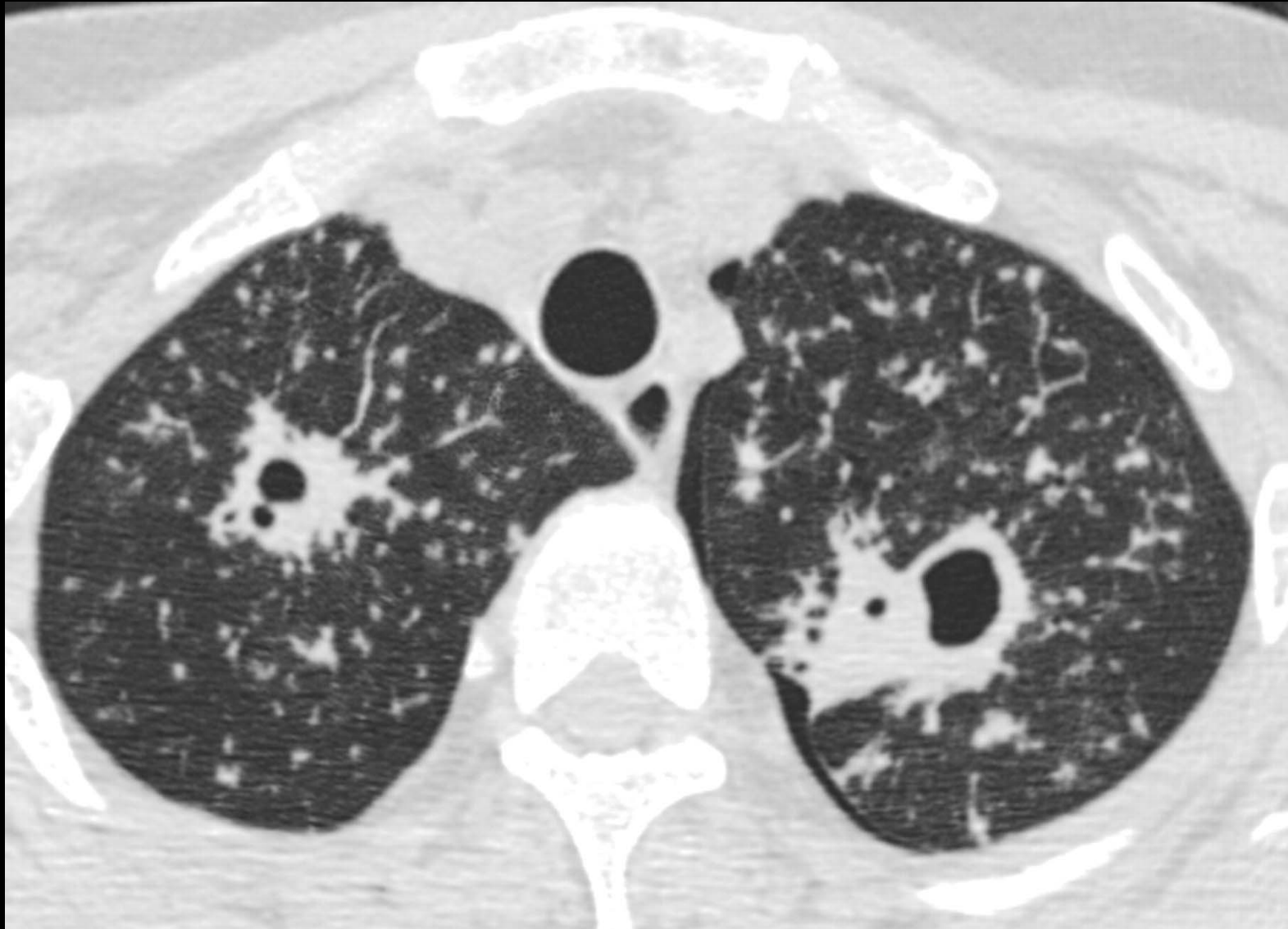

AIDS patient, CXR showed cavitory lesion, intracavitary  
nodule move with body position



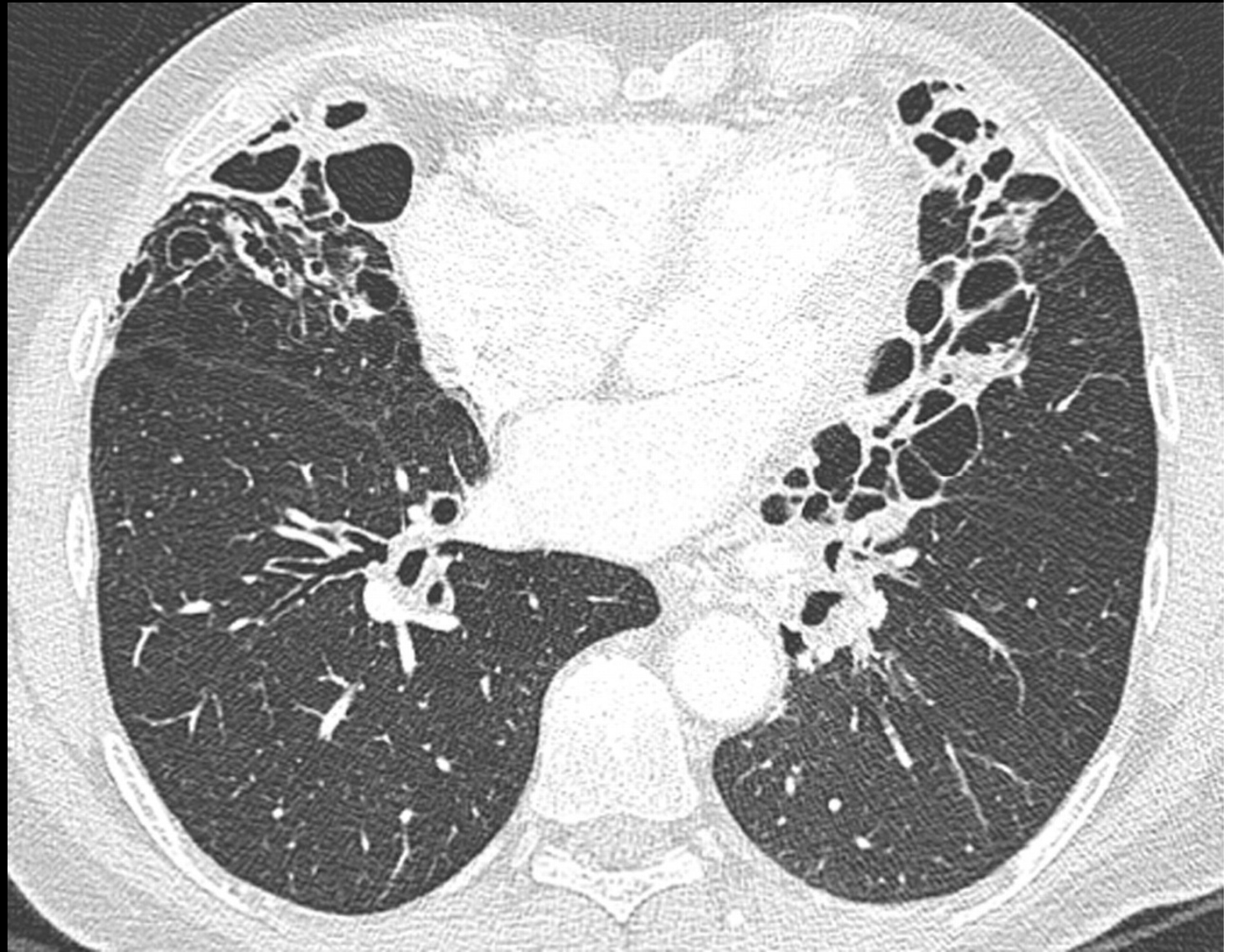
**fungal ball**

Chronic productive cough for 1 year, fever with evening rise in temperature, sweating



**TB**

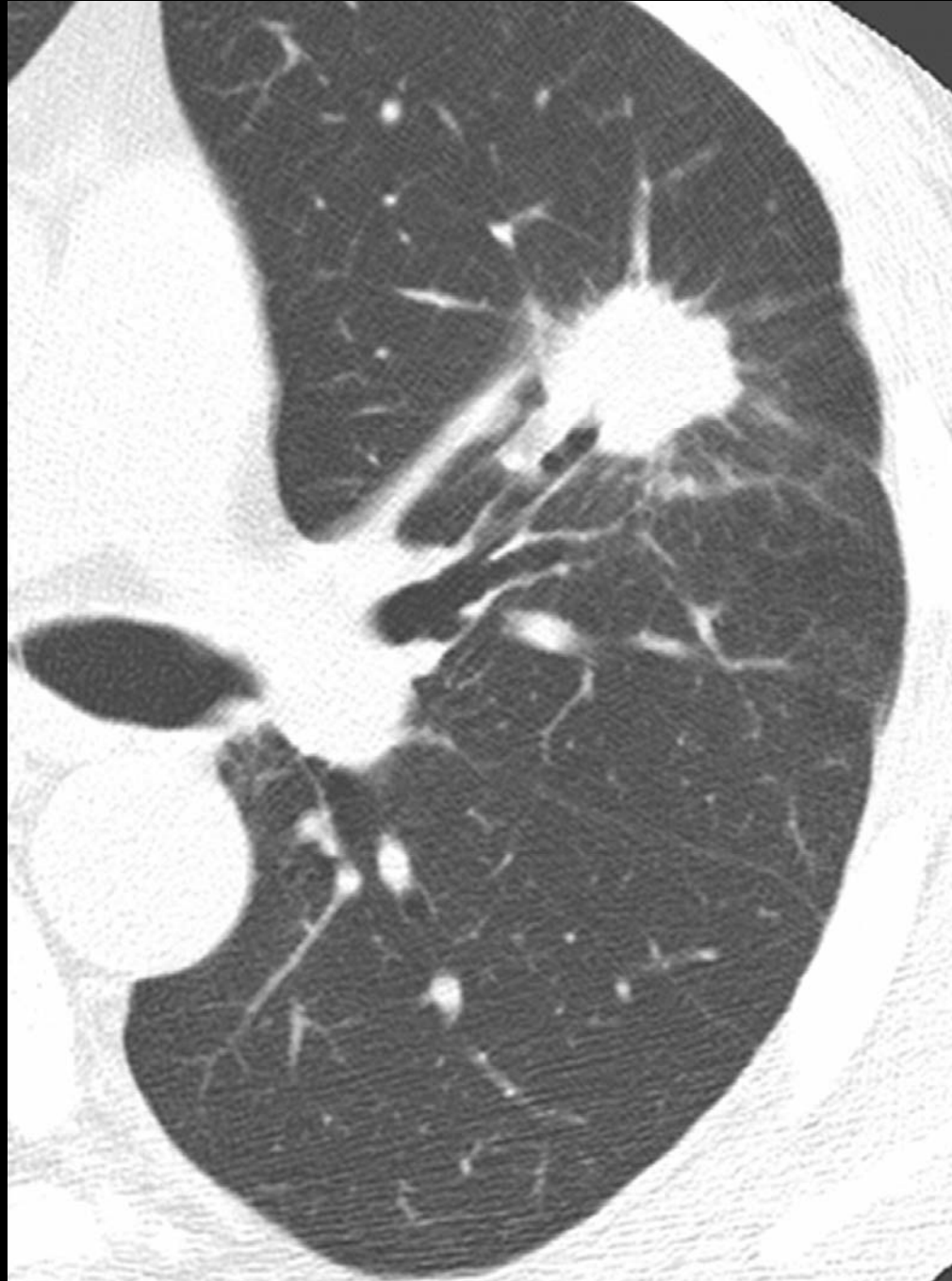
Smoking for many years, cough with bloody sputum



**bronchiectasis**

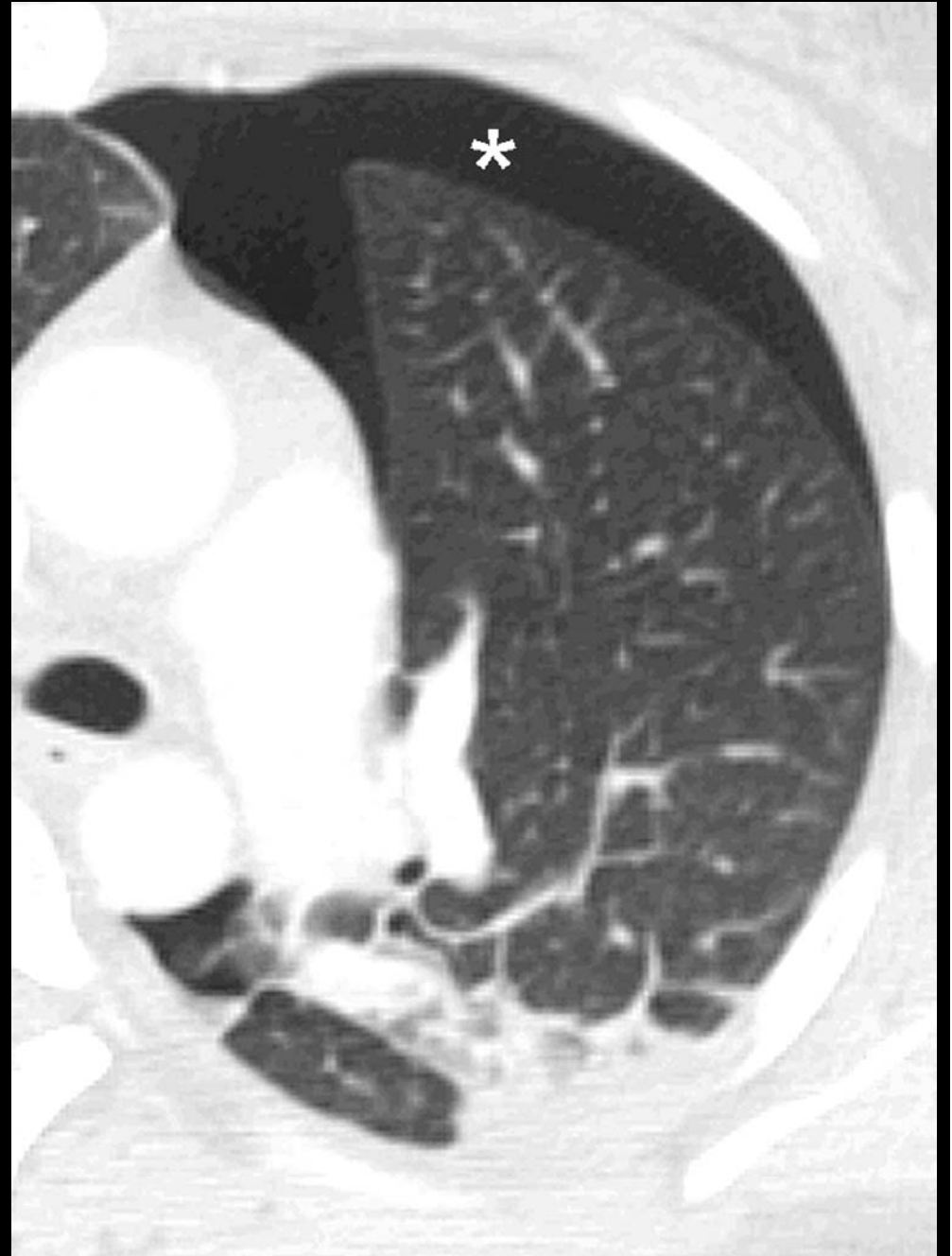Smoking 20 years

**lung cancer**



Chest trauma, rib fracture

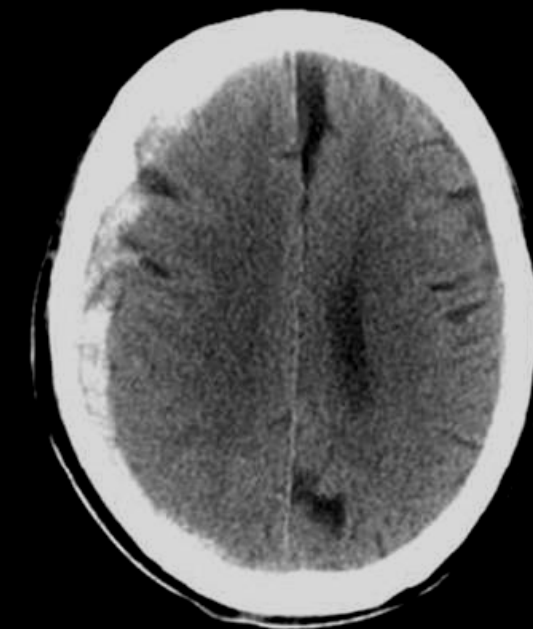
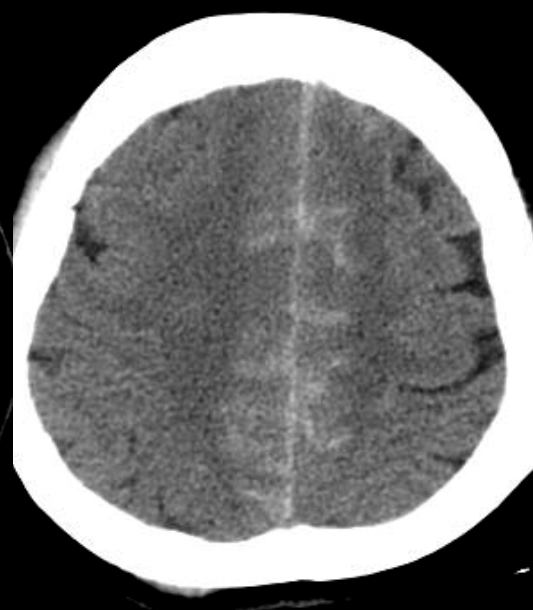
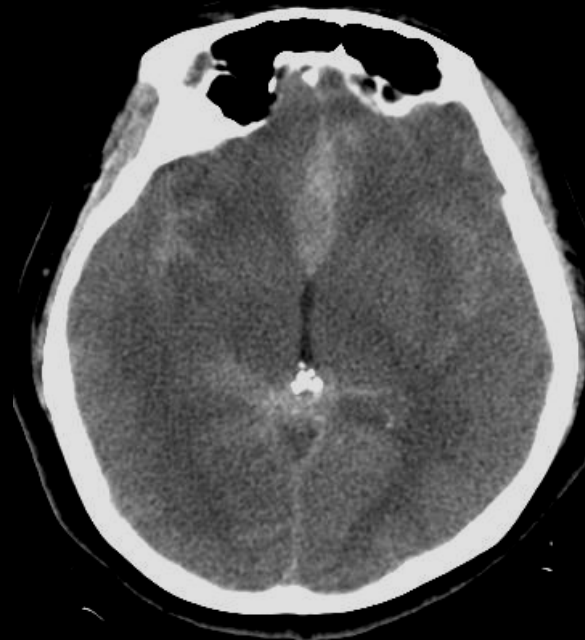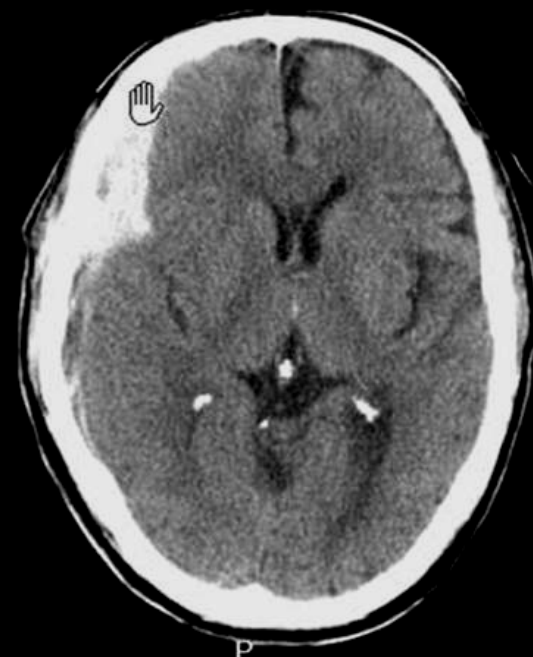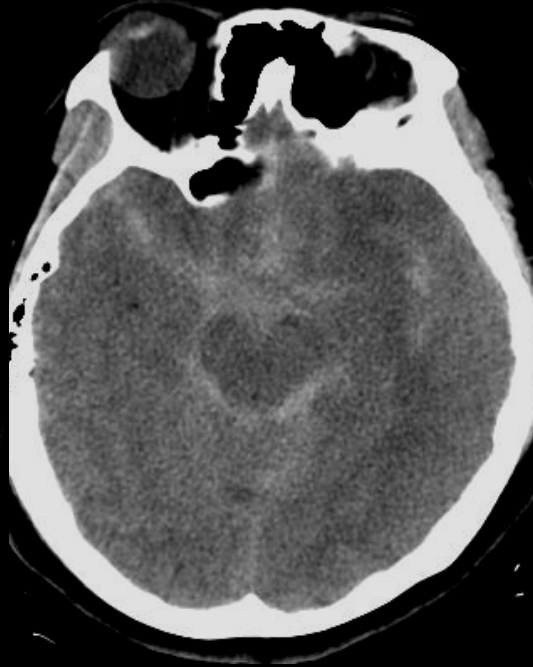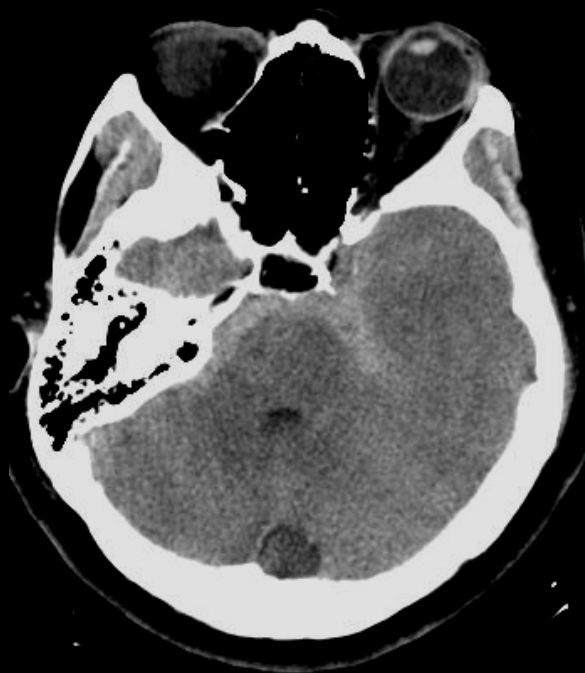**pneumothorax**



**(1) SAH (2) SDH**

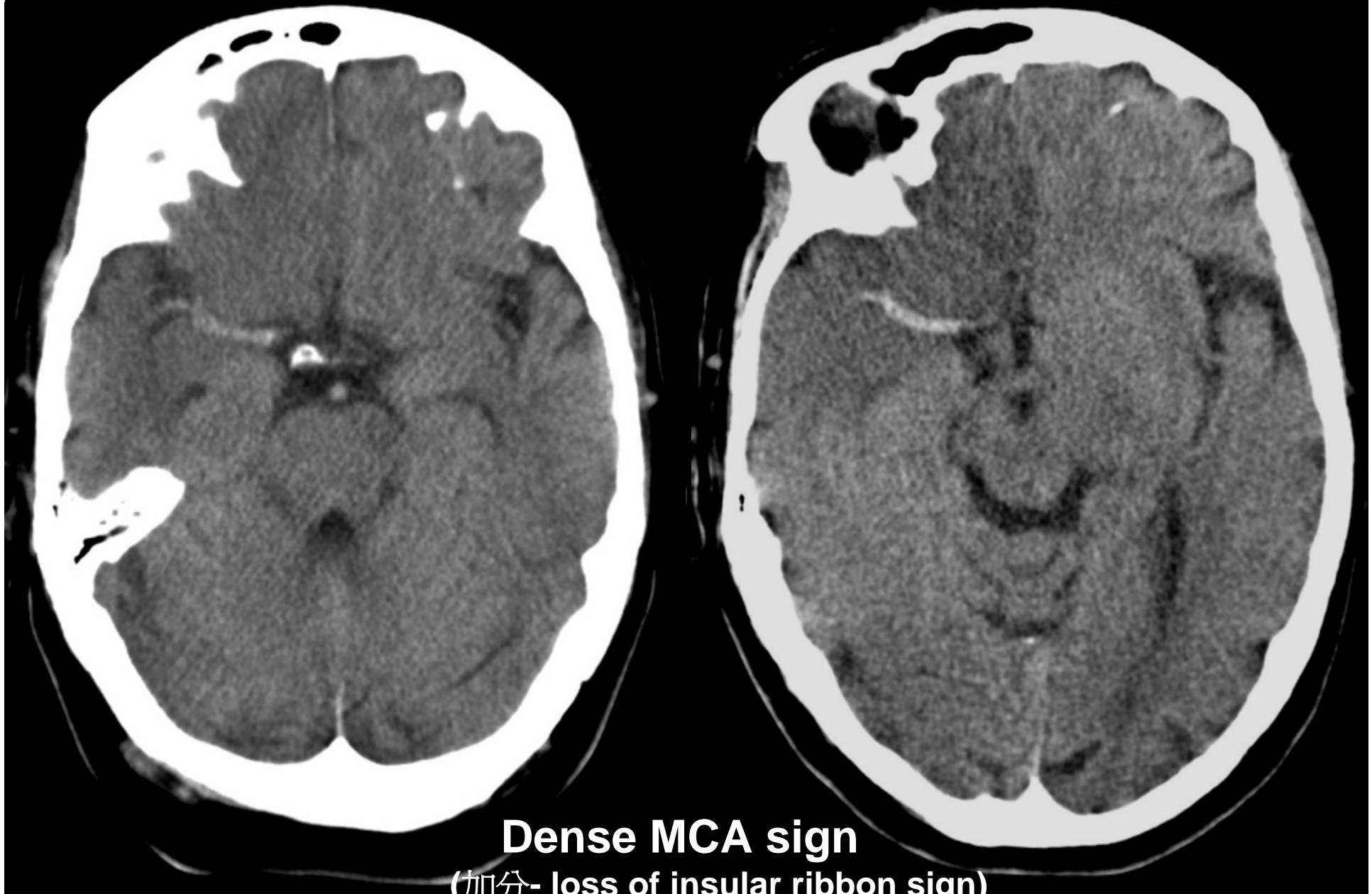
**(1), Trauma (-)**

**(2), Trauma (+)**

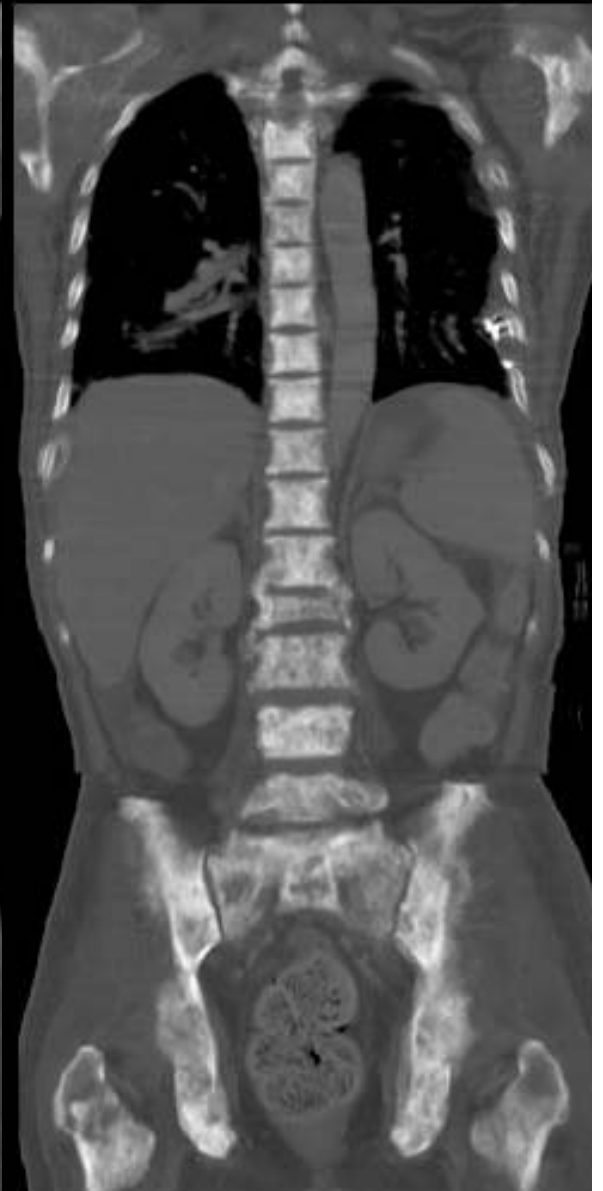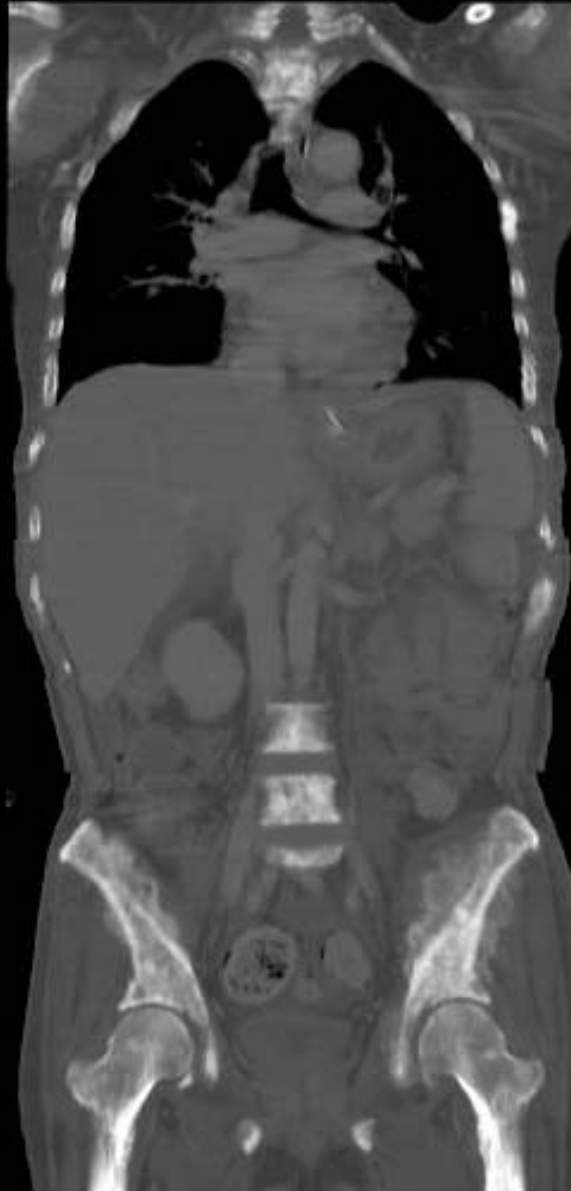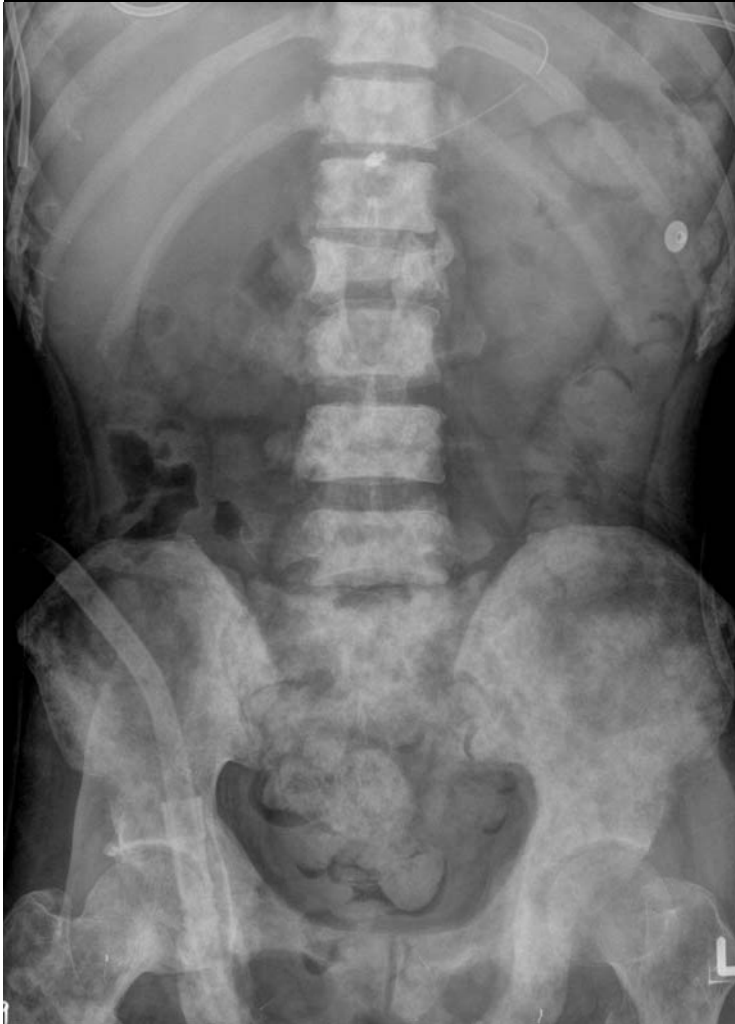


describes a radiologic sign at least

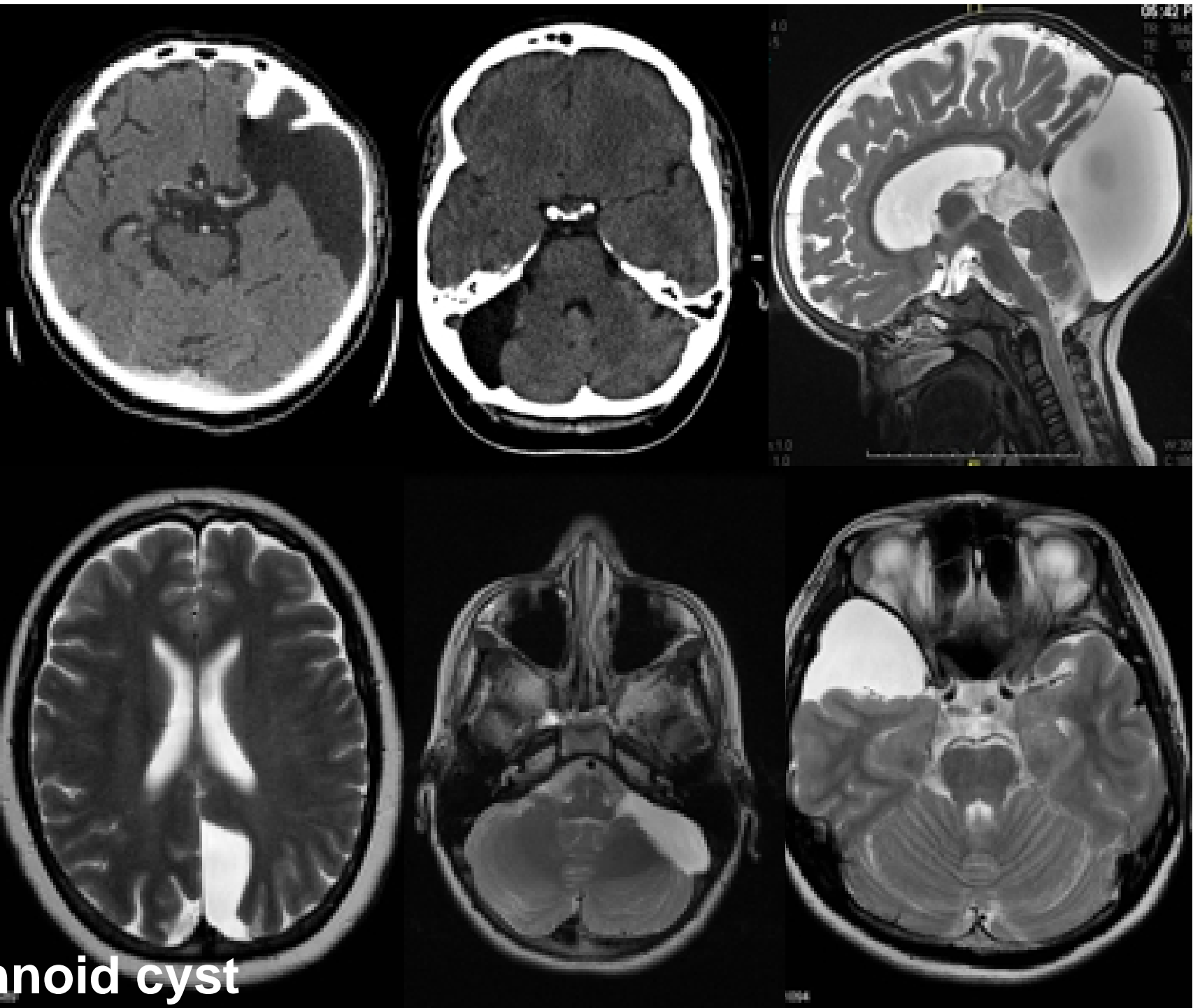
1-day after



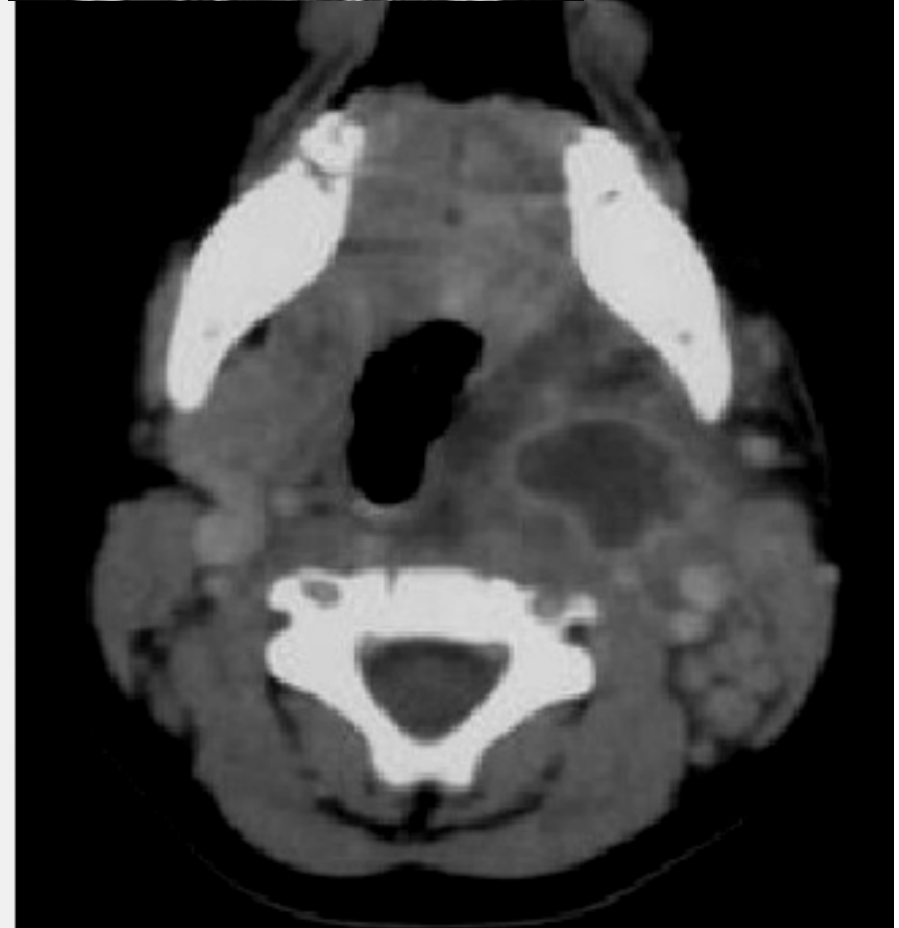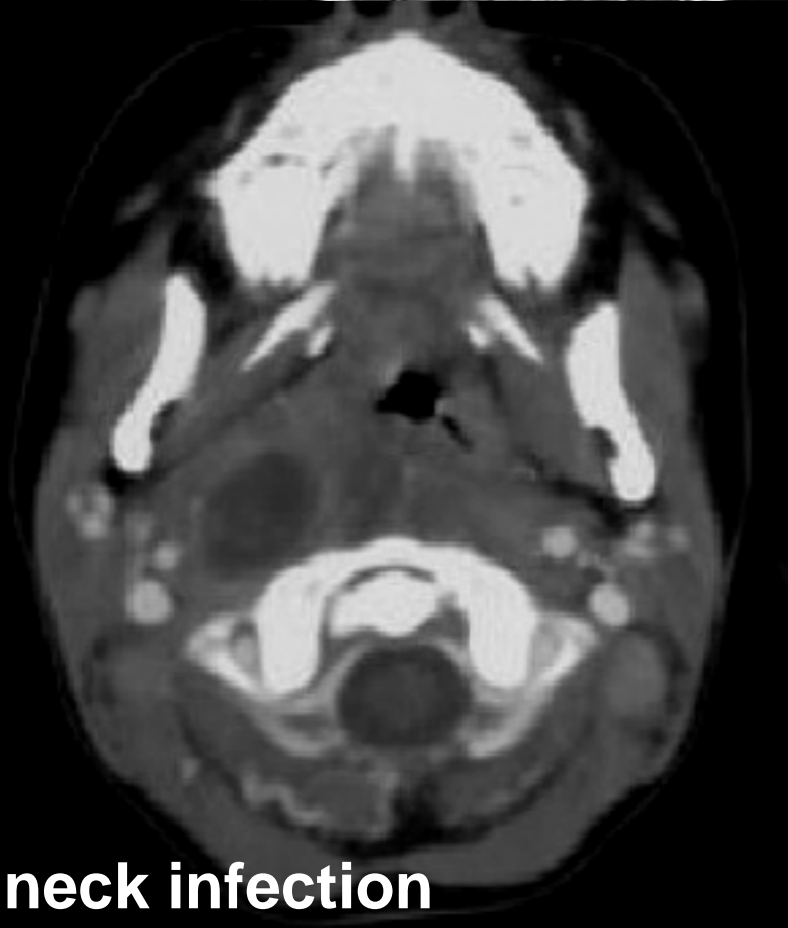
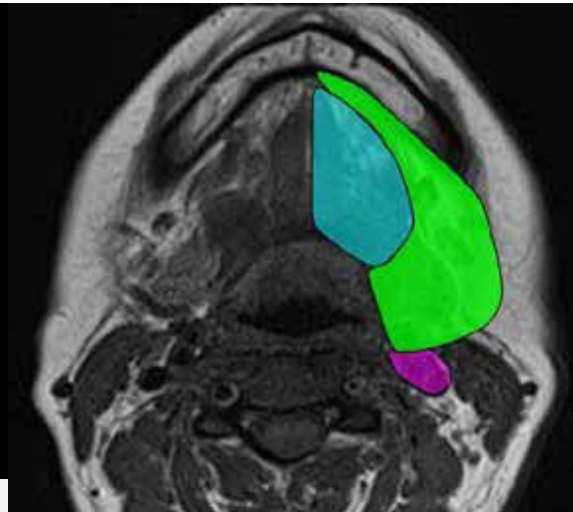
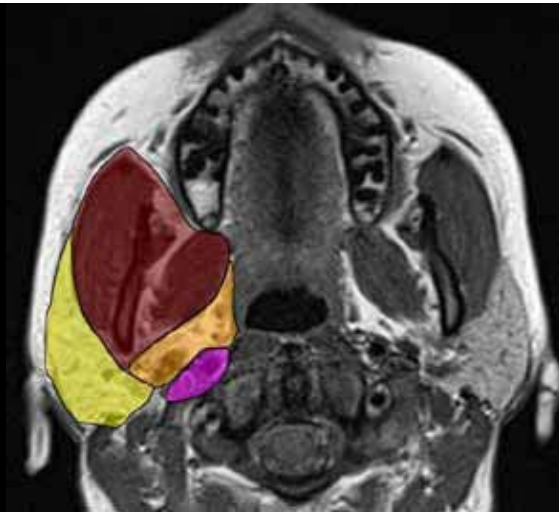**Dense MCA sign**  
(加分- loss of insular ribbon sign)



**Osteoblastic bony metastases**



**Arachnoid cyst**



**Deep neck infection**