

# 淋巴瘤診療指引

## 一、參與討論同仁

主席	彭汪嘉康院士	
	邱仲峯副院長	
附設醫院	廖裕民醫師 (血腫科)	夏和雄醫師 (血腫科)
	李婉玫副主任 (癌症中心)	吳佩玲組長 (癌症中心)
	林尹宣個管師 (癌症中心)	李玉婷個管師 (癌症中心)
萬芳醫院	賴基銘醫師 (血腫科)	張家崙醫師 (血腫科)
	劉興璟醫師 (血腫科)	陳淑玲個管師 (癌症中心)
	張嘉琦個管師 (癌症中心)	
雙和醫院	蘇勇誠醫師 (血腫科)	王緯婷個管師 (癌症中心)
臺北癌症中心	夏和雄醫師	廖裕民醫師

二、討論日期：105年11月16日

三、校稿人員：張家崙醫師 / 陳淑玲個管師

## 105 年版與上一版差異：

104 年版	105 年修訂版
何杰金氏淋巴瘤 B-2 微球蛋白 (選擇性)	
何杰金氏淋巴瘤	新增：增加臨床分期表格
何杰金氏淋巴瘤 早期預後良好定義：早期預後良好定義：(1)Age< 50 y/o (2)ESR normal(3) Stage I~II(4)No B symptoms (5)No bulky disease 在路徑圖下方	修改路徑： 早期預後良好分類：1. 部分反應→局部放療→重新評估→(+)→組織切片 2. 穩定或疾病惡化→組織切片→分(+)(-)
何杰金氏淋巴瘤 路徑線重新畫好	修改路徑：早期非預後良好分類 1. 部分反應→重新評估→(+)→局部放療→PET(+)→組織切片 2. 穩定或疾病惡化→組織切片→分(+)(-)
何杰金氏淋巴瘤 ABVD 2 個療程	
何杰金氏淋巴瘤 第 III~IV 期起始治療，為 ABVD 2 個療程，重新評估反應 (CR 及 PR) 後再加上 ABVD 4 個療程。	修改路徑：第 III~IV 期 1. 部分反應→重新評估→(+)→局部放療→PET(+)→組織切片 2. 穩定或疾病惡化→組織切片→分(+)(-)

## 104 年版

何杰金氏淋巴瘤

2. 觀察

慢性淋巴白血病 (CLL)/ 小淋巴細胞瘤 (SLL)

臨床評估 :Coombs' test ( 選擇性 ) immunopheresis( 選擇性 )

濾泡淋巴瘤 (Follicular Lymphoma)

刪除 1. 化療 6~8 療程 ( 未接受過化療者 )

濾泡淋巴瘤轉變成瀰漫性大 B 細胞淋巴瘤 (FL → DLBCL)

起始治療→無反應→ 1. 臨床試驗 2. 化療 3. 緩和療法之路徑

濾泡淋巴瘤轉變成瀰漫性大 B 細胞淋巴瘤 (FL → DLBCL)

刪除 : 放射免疫療法

胃黏膜淋巴組織相關淋巴瘤 (Gastric MALT Lymphoma)

有反應及穩定、疾病惡化、有反應→ 1. 第二線抗生素治療 2. 放射線治療

3. 化療 ± Anti-CD20 4. 觀察。

## 105 年修訂版

刪除 : Gazyva(Obinatuvzumab)(optional) 的 wating for druge

## 104 年版

非胃黏膜淋巴組織相關淋巴瘤 (Nongastric MALT Lymphoma)  
刪除此項 guideline

瀰漫性大 B 細胞淋巴瘤 / 濾泡性淋巴瘤 Gr. III(DLBCL/FL Gr. III)  
β-2 微球蛋白 (選擇性)

瀰漫性大 B 細胞淋巴瘤 / 濾泡性淋巴瘤 Gr. III(DLBCL/FL Gr. III)  
巨大腫瘤區分改為 7.5cm

瀰漫性大 B 細胞淋巴瘤 / 濾泡性淋巴瘤 Gr. III(DLBCL/FL Gr. III)  
R+C/T 6~8 cycles ± 放射治療

## 105 年修訂版

修改：

臨床分期改

1. 第 I 期
2. 第 II-IV 期

修改：

PR → 完成 R+ 化學治療 total 6~8 cycles+ 放射治療

第 I 期 → 刪除放射治療

## 104 年版

瀰漫性大 B 細胞淋巴瘤 / 濾泡性淋巴瘤 Gr. III(DLBCL/FL Gr. III)

## 1. 第 I-II 期

- (1)CR → R/T 或完成 R+C/T total 6~8cycles±R/T →觀察
- (2)PR → R/T 或完成 R+C/T total 6~8cycles±R/T →重新評估→ CR →  
觀查
- (3)SD+PD 及 PR(PR、CR、PD) → 1. 救援性化學治療 2 高劑量化學治療 +ASCT 3. 臨床試驗 4. 緩和治療

## 2. 第 III-IV 期

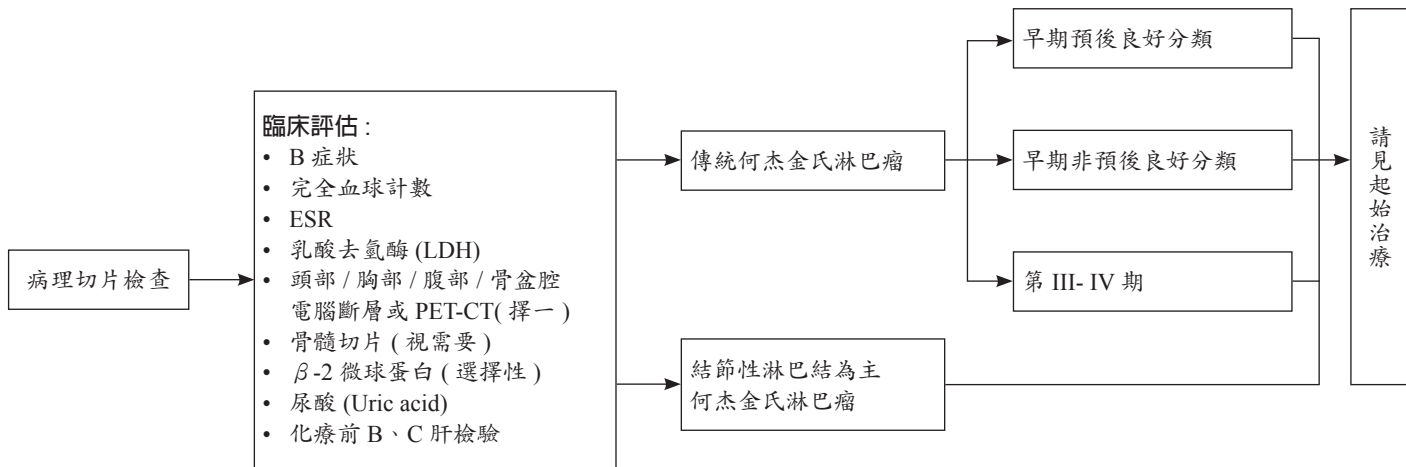
- (1)CR → R/T 或完成 R+C/T total 6~8cycles±R/T →觀察
- (2)PR → R/T 或完成 R+C/T total 6~8cycles±R/T →重新評估→ CR →  
觀查
- (3)SD+PD 及 PR(PR、CR、PD) → 1. 救援性化學治療 2 高劑量化學治療 +ASCT 3. 臨床試驗 4. 緩和治療

## 105 年修訂版

## 確診

## 臨床檢查

## 臨床分期



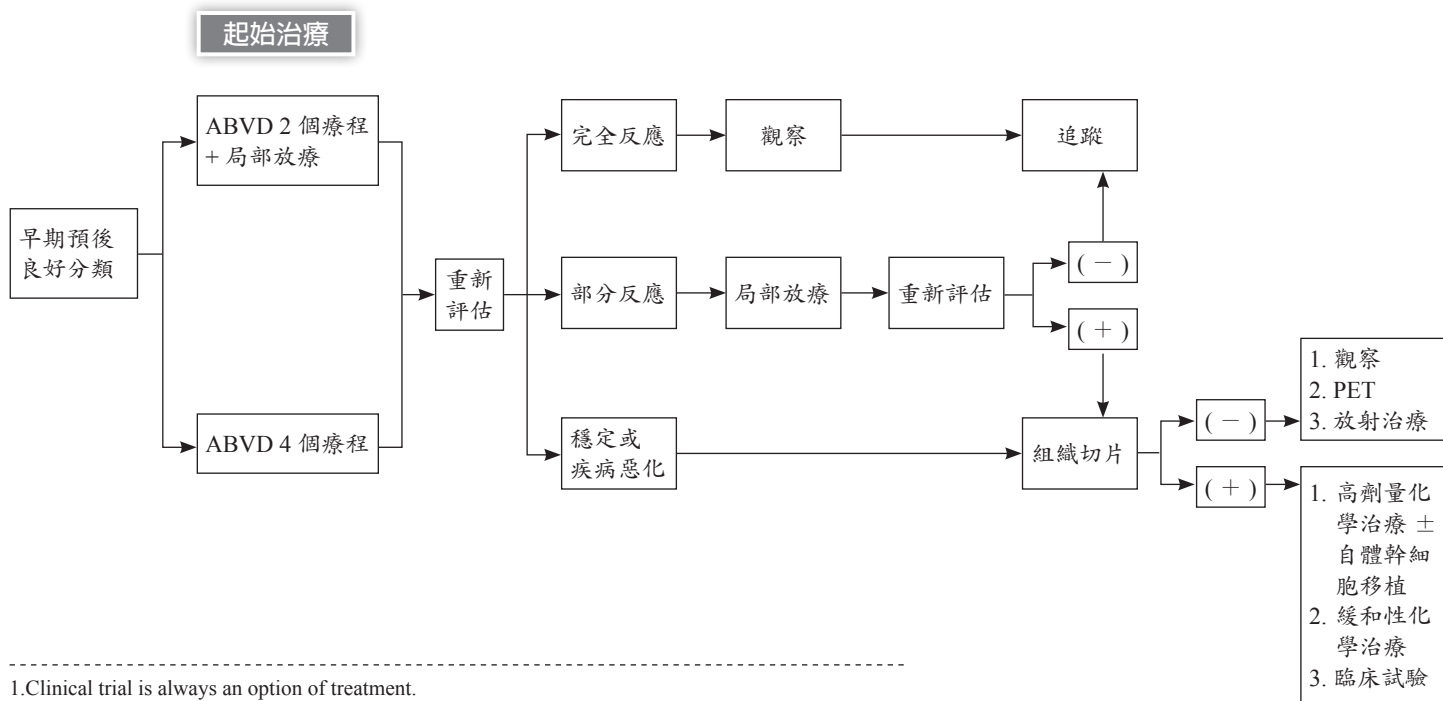
1. B symptoms : fever, night sweating, body weight loss.
2. 預後不良因子 : ESR>50, B symptoms, Nodal sites >3. bulky tumor(>10) or large mediastinum lesion(MMR>0.33).
3. Clinical trial is always an option of treatment.

## 《 淋巴瘤診療指引共識—CLASSICAL HODGKIN LYMPHOMA(CHL) 臨床分期 》

臨床分期	巨大腫瘤 ( 橫膈膜 )	淋巴結數目	(ESR)
IA	No	1	<50
IB	No	1	Any
IIA, (E) lesions 沒有淋巴結外淋巴瘤	No	<3	<50
IIA ±(E) lesions 有淋巴結外淋巴瘤	No	<4	<50
	No	≥ 4 or	≥ 50
	Yes	Any	Any
IIB ± (E) lesions 有淋巴結外淋巴瘤	No	Any	Any
	Yes	Any	Any
III-IV	Yes/No	Any	Any

# 《淋巴瘤診療指引共識—何杰金氏症 (Hodgkin lymphoma)-2》

《臨床分期：傳統何杰金氏淋巴瘤》

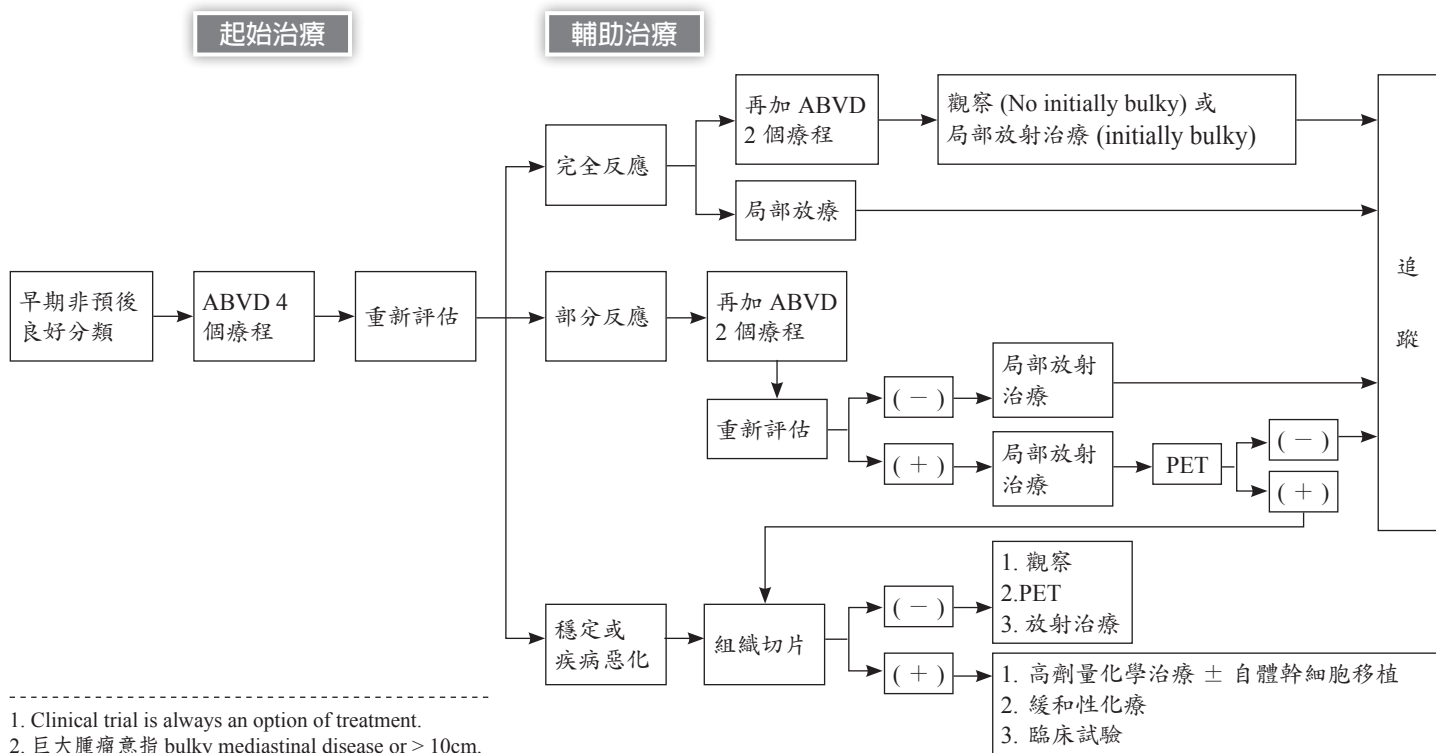


1. Clinical trial is always an option of treatment.  
 2. Rituximab may be added electively (self-paid) if CD 20 is positive in IHC stain.  
 3. 早期預後良好定義 :1.Age < 50 y/o 2.ESR normal 3.Stage I~II 4.No B symptoms 5.No bulky disease



# 《淋巴瘤診療指引共識—何杰金氏症 (Hodgkin lymphoma)-3》

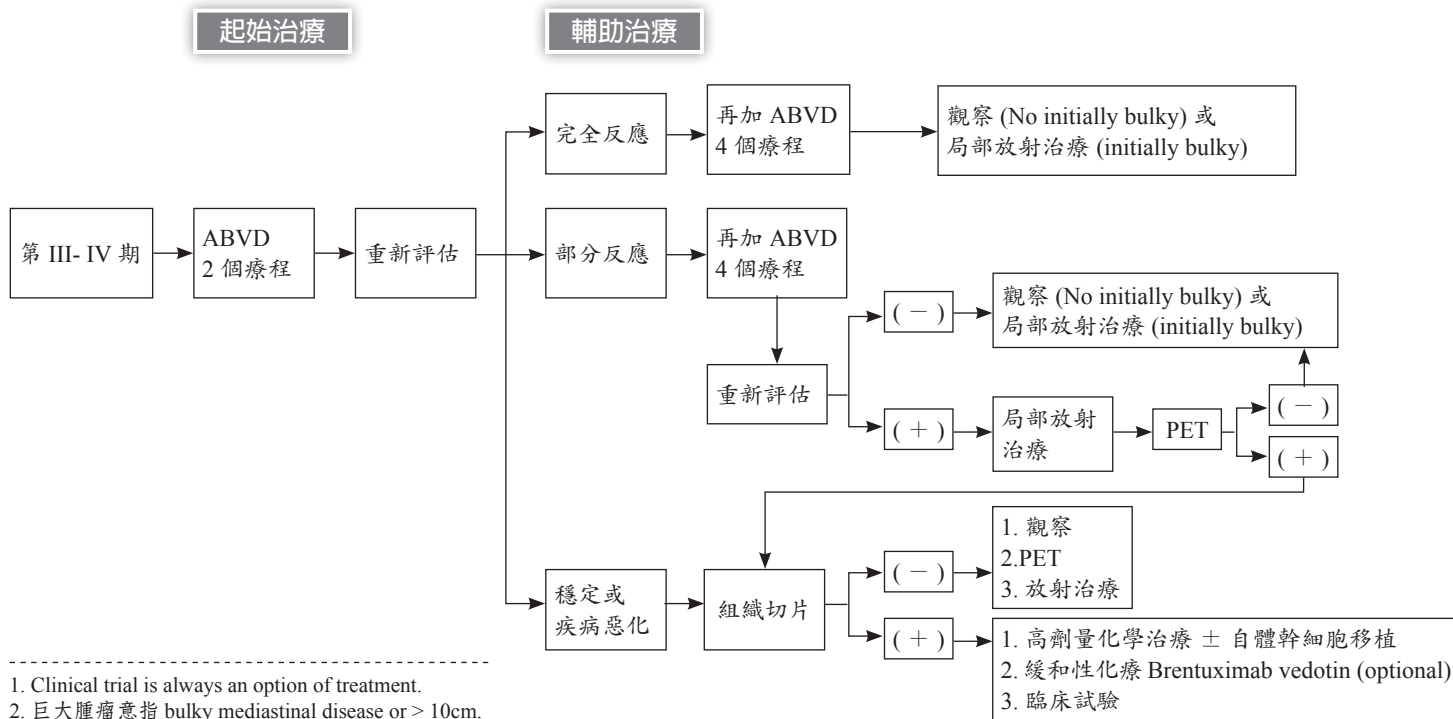
《臨床分期：傳統何杰金氏淋巴瘤》



1. Clinical trial is always an option of treatment.  
2. 巨大腫瘤意指 bulky mediastinal disease or > 10cm.

# 《淋巴瘤診療指引共識—何杰金氏症 (Hodgkin Lymphoma)-4》

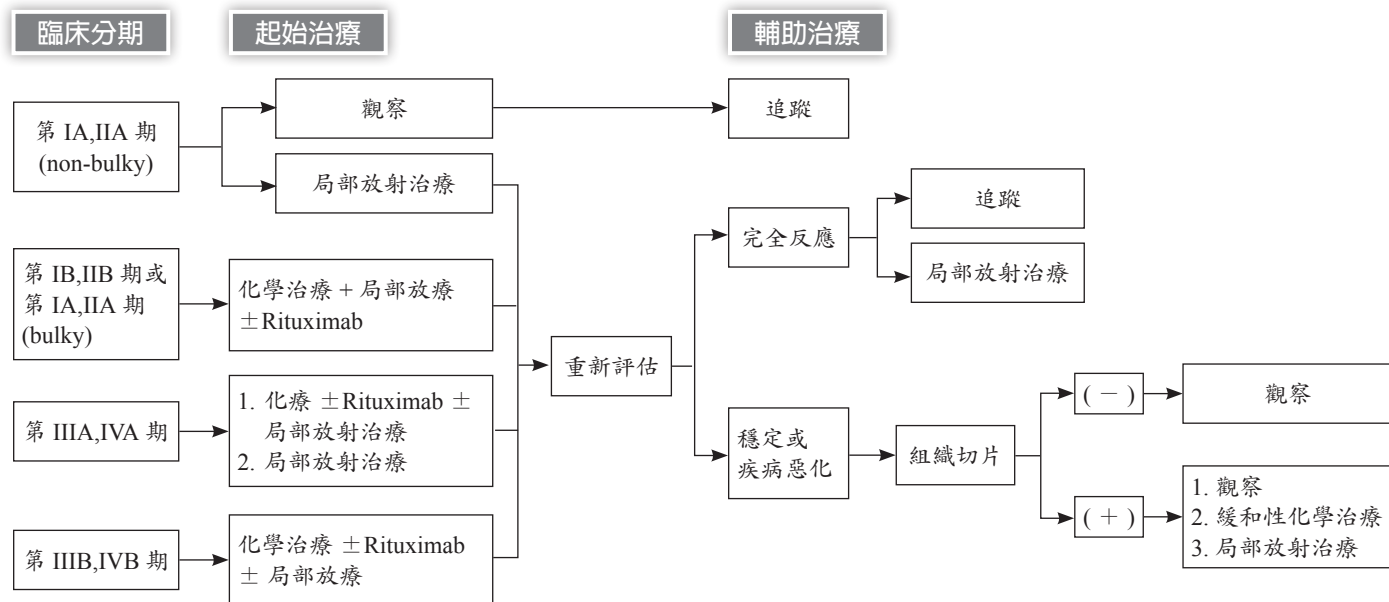
《臨床分期：傳統何杰金氏淋巴瘤》



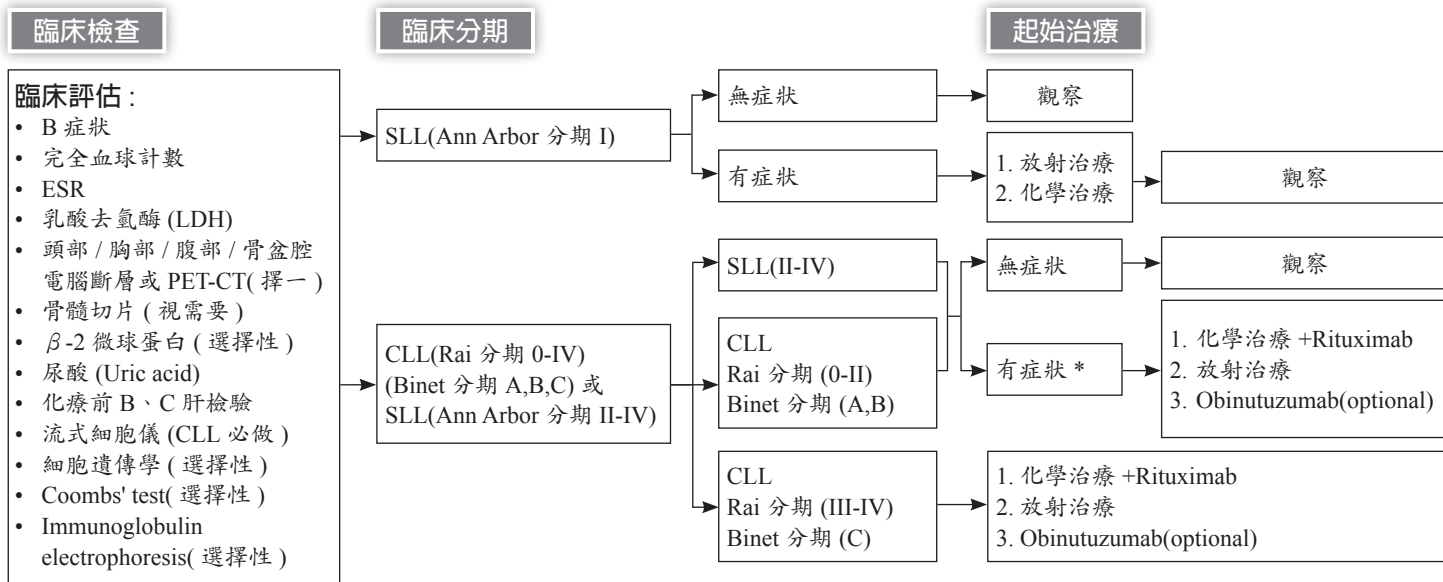
1. Clinical trial is always an option of treatment.
2. 巨大腫瘤意指 bulky mediastinal disease or > 10cm.

## 《淋巴瘤診療指引共識—何杰金氏症 (Hodgkin lymphoma)-5》

《臨床分期：結節性淋巴結為主何杰金氏淋巴瘤》



\*Clinical trial is always an option of treatment.



† Clinical trial is always an option of treatment.

† 評估有以下症狀\*：

1. Fatigue(severe) 2. Night sweats 3. Weight loss 4. Fever without infection

\* Threatened end-organ function

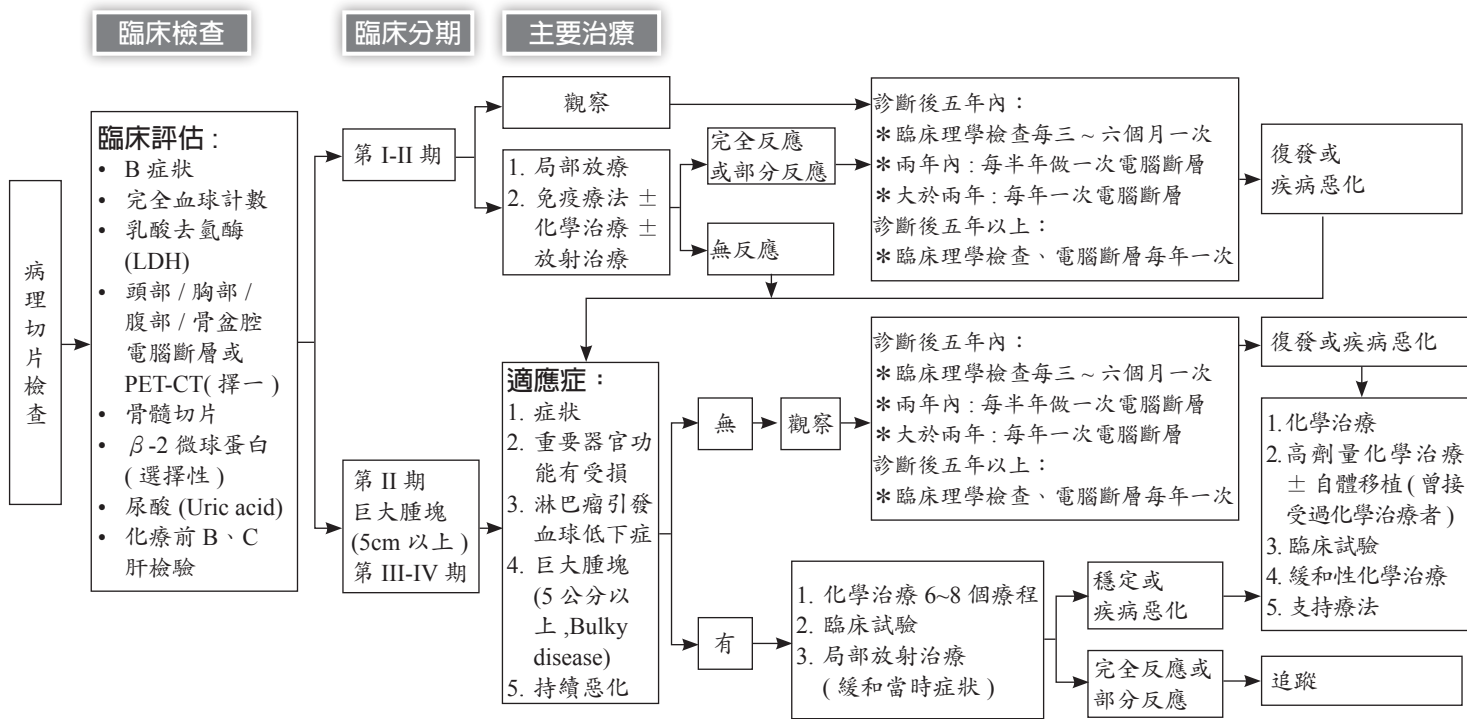
\* Progressive bulky disease(spleen>6cm below costal margin, lymph nodes>10cm)

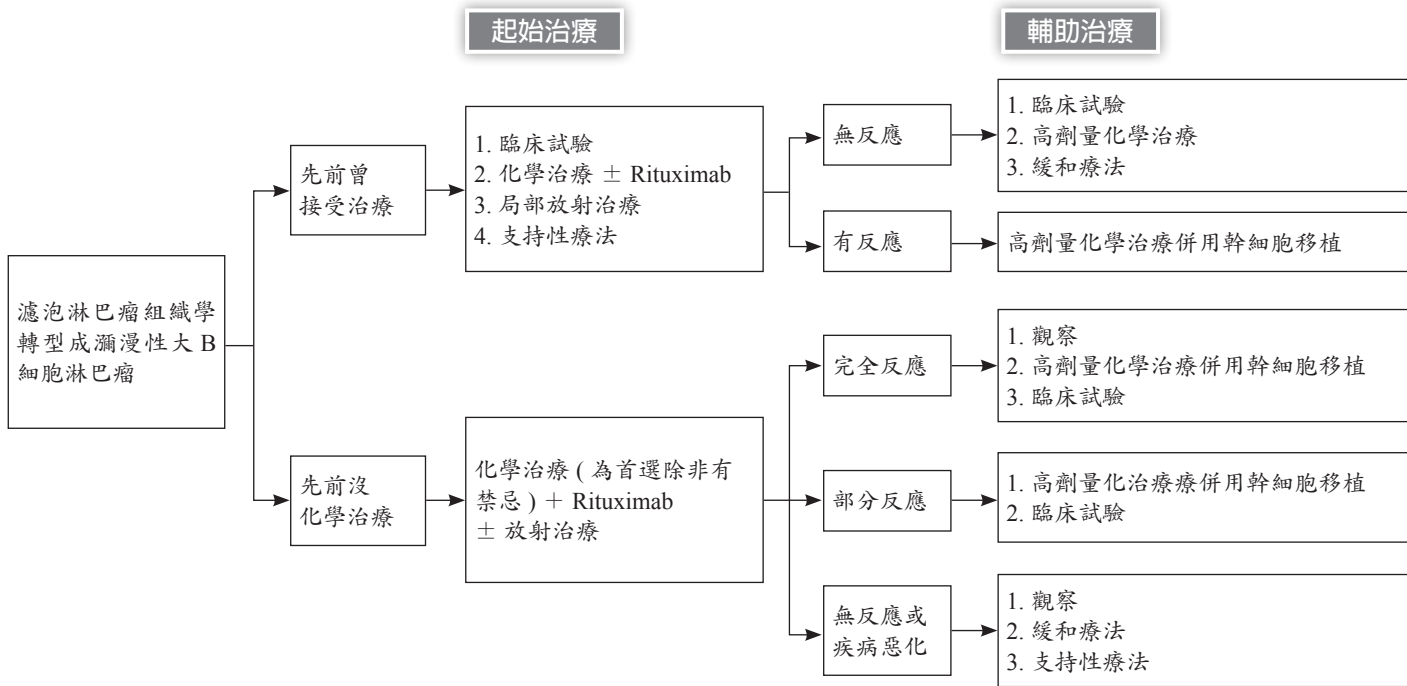
\* Progressive anemia

\* Progressive thrombocytopenia

† Gazyva(Obinutuzumab)(optional)

# 《淋巴瘤診療共識—濾泡淋巴瘤 (Follicular Lymphoma) 》





## 《淋巴瘤診療共識—胃黏膜淋巴組織相關淋巴瘤 (Gastric MALT lymphoma) -1》

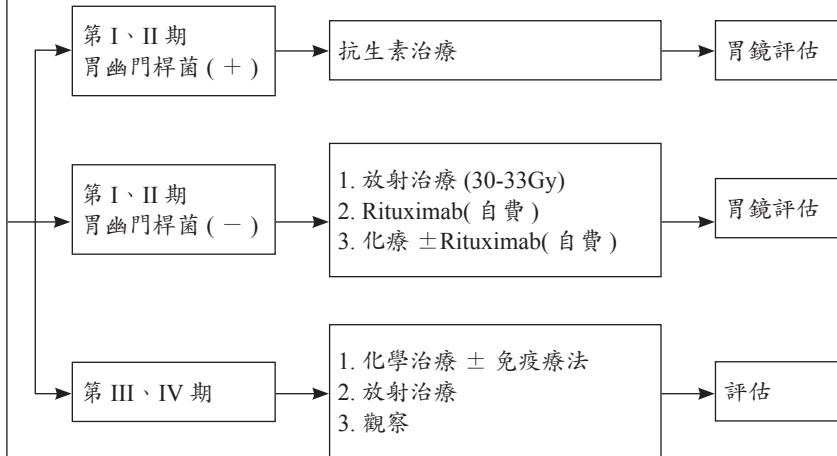
### 臨床檢查

- 理學檢查、注意胃以外的部位 (眼、皮膚)
- 體能狀態 (EC OG PS)
- CBC、白血球分類、血小板計數
- 生化常規
- LDH
- 如組織病理學檢測幽門螺桿菌陰性、則行幽門螺桿菌非侵入性檢測 (糞便抗原檢測、尿素呼氣試驗、血液抗體檢測)
- 如果擬用 Rituximab、行 B 型肝炎相關檢測
- 胸腔 / 腹腔 / 骨盆腔併顯影劑電腦斷層檢查增強診斷品質
- 超音波內視鏡 (如有) 下多個部位檢體切片
- 育齡期婦女進行妊娠試驗 (如擬行化療)
- 骨髓穿刺切片 (視需要)
- 如果需要 Anthracycline 的療程需顯示 MUGA 掃描 / 心臟超音波數據
- C 型肝炎相關檢測
- 討論生育問題和精子儲存

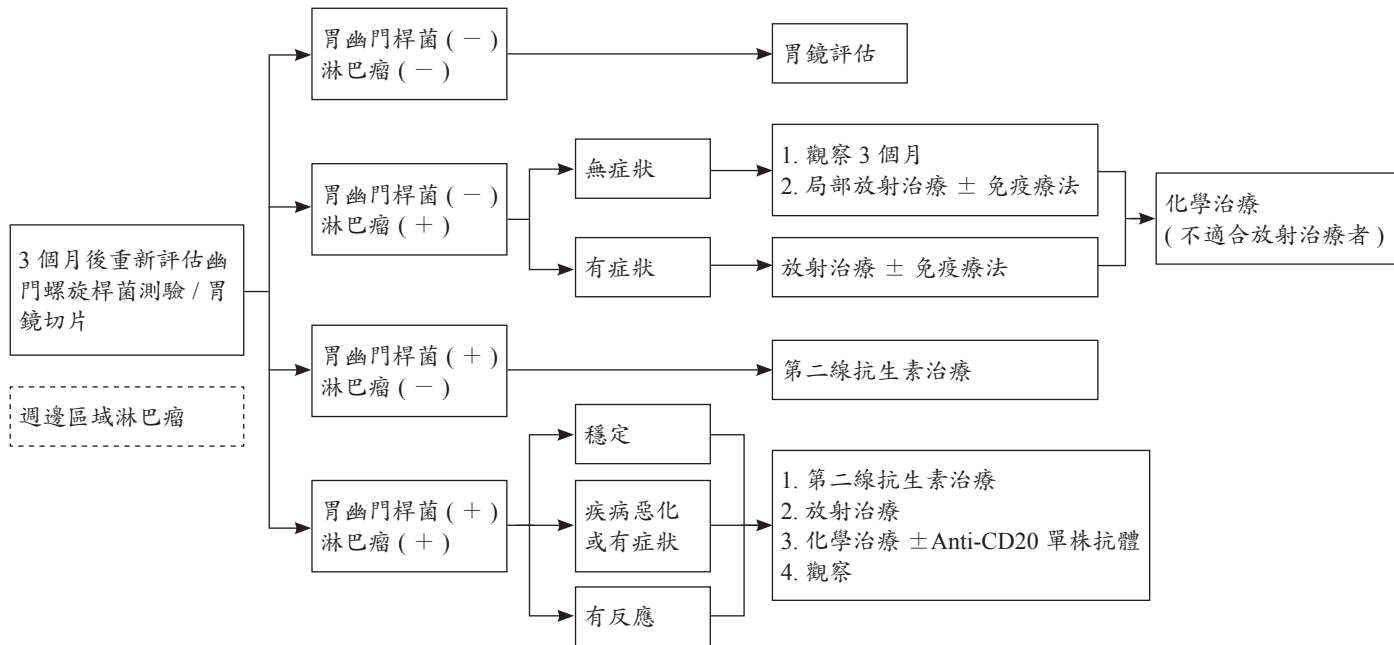
### 臨床分期

### 起始治療

### 評估



## 抗生素使用後



.....  
Clinical trial is always an option of treatment.



# 《淋巴瘤診療共識—瀰漫性大 B 細胞淋巴瘤 / 濾泡性淋巴瘤 Gr.III(DLBCL/FL Gr.III)》

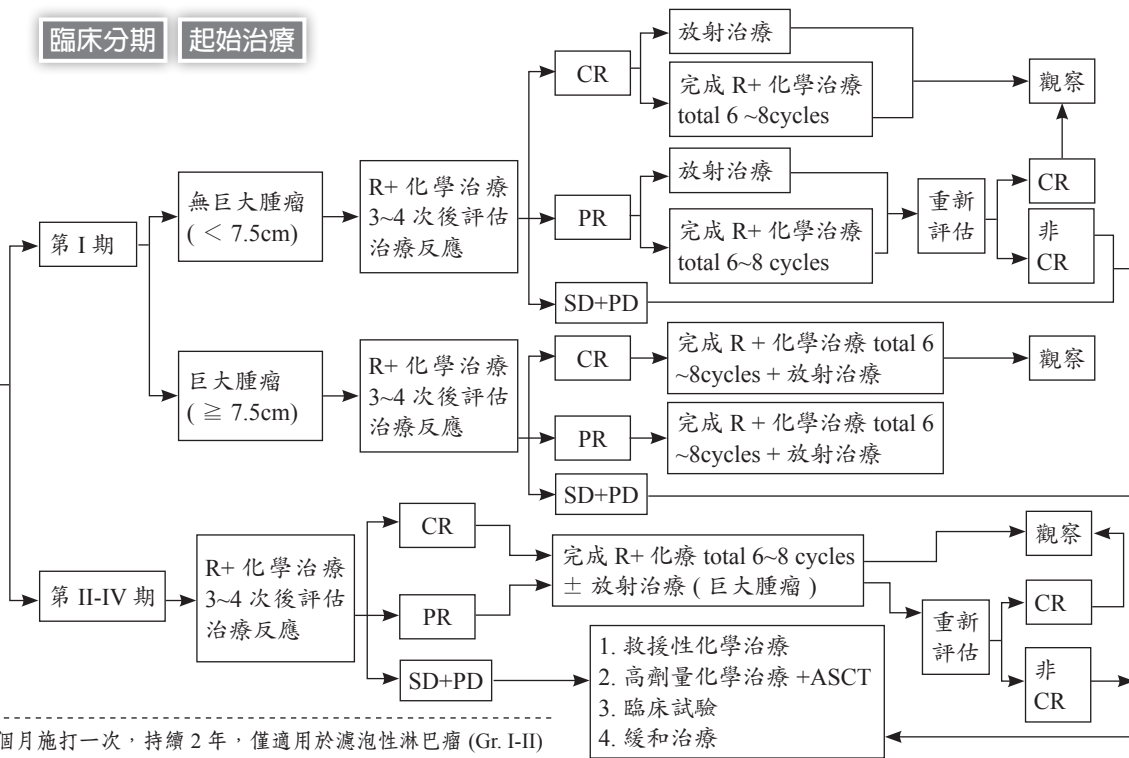
臨床檢查

臨床分期

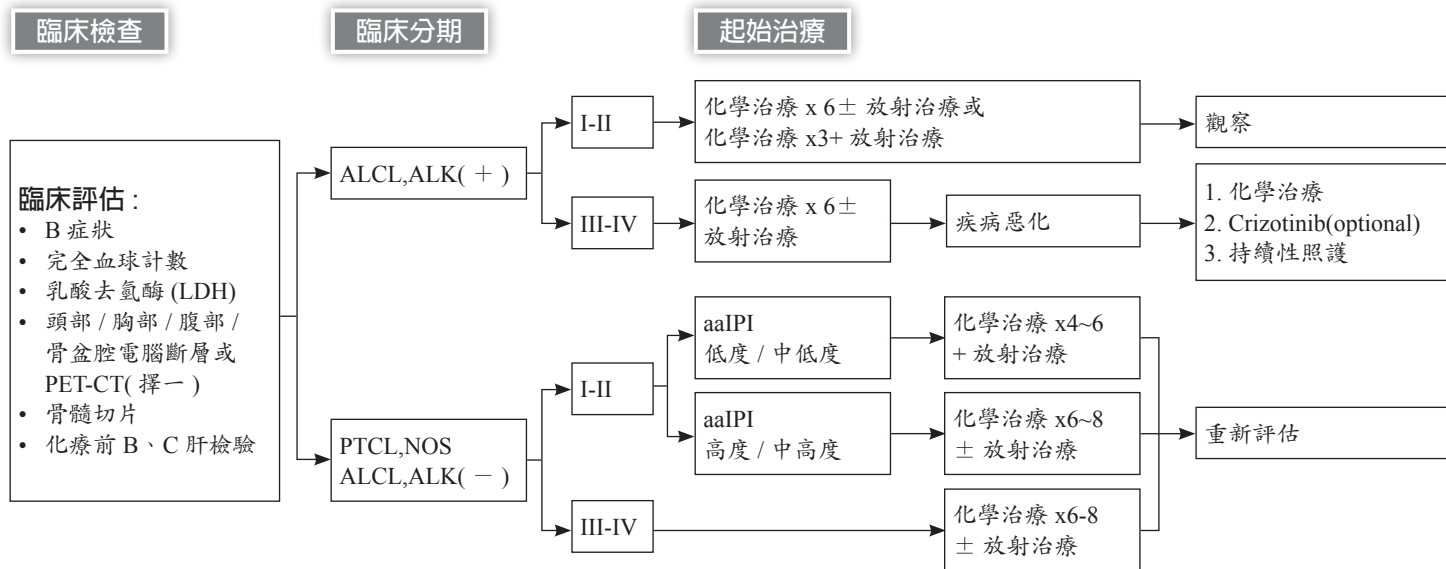
起始治療

## 臨床評估：

- B 症狀
- 完全血球計數
- 乳酸去氫酶 (LDH)
- 頭部 / 胸部 / 腹部 / 骨盆腔電腦斷層或 PET-CT( 擇一 )
- 骨髓切片
- $\beta$ -2 微球蛋白 ( 選擇性 )
- 尿酸 (Uric acid)
- 化療前 B、C 肝檢驗



\*Rituximab 持續性治療每三個月施打一次，持續 2 年，僅適用於濾泡性淋巴瘤 (Gr. I-II)  
 · Clinical trial is always an option of treatment.



1. Clinical trial is always an option of treatment.  
2. Treatment with diffuse large B cell lymphoma without rituximab.  
3. aaIPI: 年齡調整國際預後指數

## 《參考文獻》

1. NCCN clinical practice guidelines in oncology-Hodgkin Lymphoma. version 3.2016.
2. NCCN clinical practice guidelines in oncology-Hodgkin Lymphoma. version 2.2015.
3. NCCN clinical practice guidelines in oncology-Non-Hodgkin's Lymphomas. Version 2.2015.
4. WHO classification of tumours of haematopoietic and lymphoid tissues. In: Swerdlow SH, Campo E, Harris NL, et al., eds (ed 4). Lyon, France: IARC; 2008.
5. Cheson BD, Fisher RI, Barrington SF, et al. Recommendations for initial evaluation, staging, and response assessment of Hodgkin and non-Hodgkin lymphoma: the Lugano classification. *J Clin Oncol* 2014;32:3059-3068.
6. Meyer R, Gospodarowicz M, Connors J, et al. ABVD alone versus radiation-based therapy in limited-stage Hodgkin's lymphoma. *N Engl J Med* 2012;366:399-408.
7. Radford J, et al. Involved field radiotherapy versus no further treatment in patients with clinical stages IA and IIA Hodgkin Lymphoma and a negative PET scan after 3 cycles of ABVD. Results of the UK NCRI RAPID Trial [abstract]. *Blood* 2012; 120:Abstract 547.
8. Fernández de Larrea C, Martínez C, et al. Salvage chemotherapy with alternating MINE- ESHAP regimen in relapsed or refractory Hodgkin's lymphoma followed by autologous stem cell transplantation. *Ann Oncol* 2010;21(6):1211-1216.
9. Fischer K, Cramer P, Busch R, et al. Bendamustine in combination with rituximab for previously untreated patients with chronic lymphocytic leukemia: A multicenter phase II trial of the German Chronic Lymphocytic Leukemia Study Group. *J Clin Oncol* 2012;30:3209-3216. Knauf WU, Lissichkov T, Aldaoud A, et al. Phase III randomized study of bendamustine
10. Flinn IW, van der Jagt R, Kahl BS, et al. Open-label, randomized, noninferiority study of bendamustine-rituximab or R-CHOP/R-CVP in first-line treatment of advanced indolent NHL or MCL: the BRIGHT study. *Blood* 2014;123:2944-2952.
11. Rummel MJ, Niederle N, Maschmeyer G, et al. Bendamustine plus rituximab versus CHOP plus rituximab as first-line treatment for patients with indolent and mantle-cell lymphomas: an open-label, multicentre, randomised, phase 3 non-inferiority trial. *Lancet* 2013;381:1203-1210. Flinn IW, van der Jagt R, Kahl BS, et al. Open-label, randomized, noninferiority study of bendamustine-rituximab or R-CHOP/R-CVP in first-line treatment of advanced indolent NHL or MCL: the BRIGHT

- study. *Blood* 2014;123:2944-2952.
12. Salles GA, Seymour JF, Offner F, et al. Rituximab maintenance for 2 years in patients with high tumour burden follicular lymphoma responding to rituximab plus chemotherapy (PRIMA): A phase 3, randomised controlled trial. *The Lancet* 2011;377:42-51.
  13. Feugier P, Van Hoof A, Sebban C, et al. Long-term results of the R-CHOP study in the treatment of elderly patients with diffuse large B-cell lymphoma: a study by the Groupe d'Etude des Lymphomes de l'Adulte. *J Clin Oncol* 2005;23:4117-4126.
  14. Weidmann E, Kim SZ, Rost A, et al. Bendamustine is effective in relapsed or refractory aggressive non-Hodgkin's lymphoma. *Ann Oncol* 2002;13:1285-1289.
  15. Salles GA, Seymour JF, Offner F, et al. Rituximab maintenance for 2 years in patients with high tumour burden follicular lymphoma responding to rituximab plus chemotherapy (PRIMA): A phase 3, randomised controlled trial. *The Lancet* 2011;377:42-51.
  16. Eichhorst B, Fink AM, Busch R, et al. Frontline chemoimmunotherapy with fludarabine (F), cyclophosphamide (C), and rituximab (R) (FCR) shows superior efficacy in comparison to bendamustine (B) and rituximab (BR) in previously untreated and physically fit patients (pts) with advanced chronic lymphocytic leukemia (CLL): Final analysis of an international, randomized study of the German CLL Study Group (GCLLSG) (CLL10 Study)[abstract]. *Blood* 2014;124:Abstract 19.
  17. Eichhorst B, Fink AM, Busch R, et al. Frontline chemoimmunotherapy with fludarabine (F), cyclophosphamide (C), and rituximab (R) (FCR) shows superior efficacy in comparison to bendamustine (B) and rituximab (BR) in previously untreated and physically fit patients (pts) with advanced chronic lymphocytic leukemia (CLL): Final analysis of an international, randomized study of the German CLL Study Group (GCLLSG) (CLL10 Study)[abstract]. *Blood* 2014;124:Abstract 19.
  18. Coiffier B, Thieblemont C, Van Den Neste E, et al. Long-term outcome of patients in the LNH-98.5 trial, the first randomized study comparing rituximab-CHOP to standard CHOP chemotherapy in DLBCL patients: a study by the Groupe d'Etudes des Lymphomes de l'Adulte. *Blood* 2010;116:2040-2045.
  19. Salles G, Seymour JF, Feugier P, et al. Updated 6 year follow-up of the PRIMA study confirms the benefit of 2-year rituximab maintenance in follicular lymphoma patients responding to frontline immunochemotherapy [abstract]. *Blood* 2013;122:Abstract 509.

20. Cunningham D, Hawkes EA, Jack A, et al. Rituximab plus cyclophosphamide, doxorubicin, vincristine, and prednisolone in patients with newly diagnosed diffuse large B-cell non-Hodgkin lymphoma: a phase 3 comparison of dose intensification with 14-day versus 21-day cycles. *Lancet* 2013;381:1817-1826.
21. Gisselbrecht C, Glass B, Mounier N, et al. Salvage regimens with autologous transplantation for relapsed large B-cell lymphoma in the rituximab era. *J Clin Oncol* 2010;28:4184-4190.